



TRIGEMINAL NEURALGIA: NEUROPATHIC PAIN ORIGINATING IN THE CNS

P. Di Emidio * and D. Cardinelli

Oral and Maxillo-Facial Unit, ASL Teramo - G. Mazzini Hospital, Teramo, Italy;

*Correspondence to:

Dr Paolo Di Emidio,
Oral and Maxillo-Facial Unit,
ASL Teramo - G. Mazzini Hospital,
Teramo, Italy.
e-mail: paolodiemidio@gmail.com

ABSTRACT

Trigeminal neuralgia (TN) is a condition characterized by recurrent severe paroxysmal pain and neurovascular dysfunction. The pain can occur sporadically or can be triggered by mild mechanical insults, and is described as being similar to that of an electric shock. The pain is often restricted to one side of the face, and the duration ranges from seconds to minutes. TN is caused by the loss of the myelin sheath that surrounds Schwann cells of the trigeminal nerve. This demyelization exposes the nerve, rendering it vulnerable, and causes the axon to become sensitive and hyperexcitable. Therapeutic treatments for TN include the use of sodium channel blockers such as carbamazepine and oxcarbazepine, and when this is not effective, surgical intervention is suggested, such as microvascular decompression and gamma knife radiosurgery, with the main goal being to alleviate the severe pain in the patient and thus improve quality of life.

KEYWORDS: *trigeminal neuralgia, pain, neuropathy, nerve, treatment, surgery*

INTRODUCTION

Trigeminal neuralgia (TN) is a disorder characterized by recurrent severe paroxysmal pain that is restricted to the trigeminal area and presents neurovascular dysfunction (1). TN can be classified into mild idiopathic TN, classic TN with morphological changes of the trigeminal root near the pons, and secondary TN due to other diseases (2). The disorder often occurs on one side of the face and affects one or more parts of the trigeminal nerve (3). Neuropathic pain is a unilateral disorder that can occur sporadically or can also be caused by mild mechanical insults. The duration of the pain ranges from just a few seconds to up to two minutes (4). Various daily activities such as drinking, eating, chewing, speaking, combing the hair, yawning, etc. can trigger this neuralgic pain (5).

TN generally arises between the ages of 40 and 60, with an incidence of approximately 16 individuals per 100,000. It affects mostly women and is characterized by intermittent pain that is described as similar to electric shocks (6). In approximately 12-18% of patients, secondary TN can be caused by benign tumors or multiple sclerosis (7). The disease can appear sporadically in children and could be due to genetic alterations that contribute to the pathological state. Moreover, TN causes very severe facial pain, which can present in different forms (8). The patient feels pain in the second maxillary or third mandibular area of the face, with the right side being affected with greater incidence. The disease usually affects only one side of the face and is rarely bilateral (9). When it does occur bilaterally, it provokes great concern

Received: 22 February, 2024
Accepted: 19 March, 2024

2974-6345 (2024)

Copyright © by BIOLIFE

This publication and/or article is for individual use only and may not be further reproduced without written permission from the copyright holder. Unauthorized reproduction may result in financial and other penalties. Disclosure: all authors report no conflicts of interest relevant to this article.

because there could be other underlying causes, such as tumors. Furthermore, patients suffering from this painful disease can experience difficulty in sleeping and can develop anxiety and depression (10).

DISCUSSION

In TN, the trigeminal nerve leaks the myelin sheath surrounding its Schwann cells due to vascular problems (11). Neurophysiological and histological studies show that the loss of the myelin sheath makes the nerve vulnerable, and the axon becomes hypersensitive and hyperexcitable (12) (Fig.1). The fibers that demyelize are the non-nociceptive and more sensitive type II sensory A β fibers (13). Hyperexcitability may cause high-frequency writhing in the patient that may be unrelated to neuropathic pain (14). Facial pain can be continuous and different from paroxysmal pain. The demyelization of the nerve root causes damage to the nociceptive system by inhibiting it, which is an effect that can also occur after surgical treatment (15).

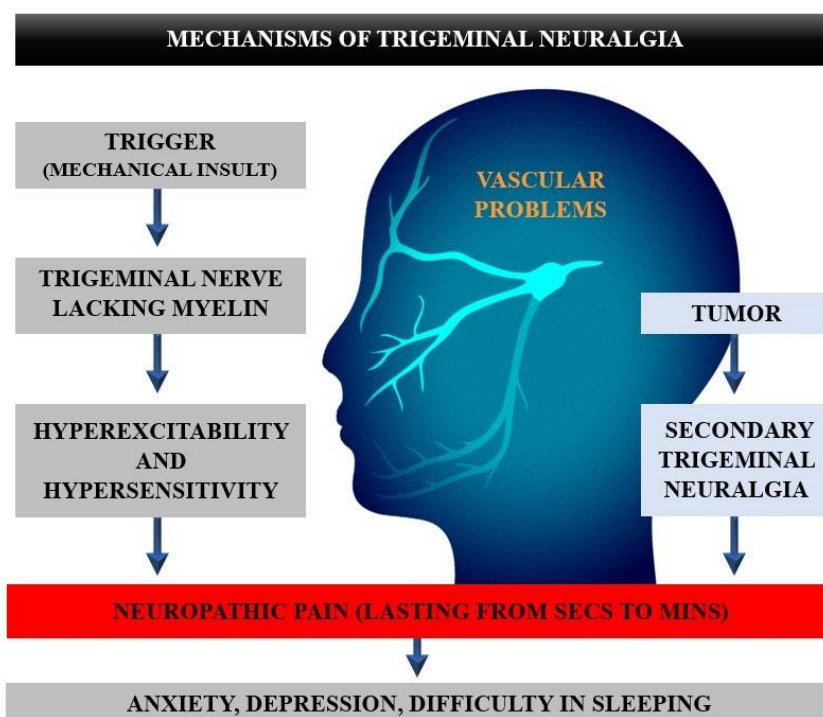


Fig. 1. A trigger, which is often a mechanical insult, activates the trigeminal nerve that lacks myelin and is hyperexcitable and hypersensitive, resulting in neuropathic pain that can lead to anxiety, depression, and sleep problems. A tumor can cause secondary trigeminal neuralgia, which provokes neuropathic pain.

Diagnosis and Treatment

The diagnosis of TN is made based on the medical history of the patient that is conducted by neurologists and/or maxillofacial experts in the field (16) (Table I). The treatment of acute pain must be specifically and promptly addressed by doctors, as suggested by the International Headache Society (IHS) and the International Association for the Study of Pain (IASP) (17).

Table I. Diagnostic criteria for trigeminal neuralgia.

• Local facial pain on the trigeminal nerve	• Age of onset less than 40 years
• Sudden pain	• Difficulty controlling pain
• Periodicity of onset of pain	• Poor response to carbamazepine
• Pain remission	• Family history of the disease
• Reduction of pain attacks after pharmacological treatment	• Episodes of pain that is similar to electric shock

Therapeutic treatment often includes drugs and may also include surgical interventions such as radio surgery, microvascular decompression, and deep neuromodulator stimulation of the brain and motor cortex (18). Drug therapy is considered the first line in treatment but is not always effective and can cause unwanted side effects. The most widely used pharmaceutical is carbamazepine, a blocker of voltage-gated and frequency-dependent sodium channels which is an anticonvulsant and analgesic drug used to control seizures and bipolar disorder (3). Although the use of sodium channel blockers such as carbamazepine and oxcarbazepine are effective, carbamazepine is often more tolerable. However, further studies are needed to understand the real mechanisms of these two drugs.

Therapeutic drugs can generate side effects such as dizziness, ataxia, diplopia, and increased levels of aminotransferase (also called transaminase), ALT, GPT, or SGPT, which is a fundamental enzyme for our body, especially in the brain and liver (19). Normally, the presence of this enzyme is minimal, but in the case of trigeminal neuropathy, the enzyme, which represents a negative marker for the organism, is released into the body in considerable quantities and ends up directly in the blood (20).

Furthermore, drugs that inhibit serotonin receptors or target the calcitonin gene are often helpful (21). Therefore, monoclonal antibodies against calcitonin gene-related peptide (CGRP) have shown an effective therapeutic effect against headaches (22).

Surgical procedures

When drugs have no effect on chronic trigeminal neuralgia in patients, our group at the Maxillofacial Surgical Unit of the "G. Mazzini" Civil Hospital in Teramo, Italy, suggests the surgical route. Surgery has been shown to be effective in reducing the severity and frequency of neuralgia attacks and allows the patient to avoid excessive doses of therapeutic drugs (23). The study of TN in recent years has seen notable updates in surgical methods, magnetic resonance imaging (MRI), classification, and clinical diagnosis (24). Diagnostic difficulties are often present since many patients suffering from this pathology present both proximal attacks and continuous localized pain. But these difficulties are now overcome with new MRI methods that are capable of distinguishing a small neurovascular contact and real vascular compromise (25).

The most widely used and effective surgical interventions are microvascular decompression and gamma knife radiosurgery, with the help of MRI. Surgery may involve the peripheral block of the branches of the trigeminal nerve (neurectomy) which anesthetizes the neuralgic part of the face. However, this procedure is rarely used as it is too painful (26). Other surgical methods involve damaging the trigeminal ganglion using radiofrequency thermocoagulation, treatment with glycerol, or through mechanical compression (27). Alternatively, a lesion of the trigeminal root can be performed with a gamma knife, without damaging the pons. This is a more updated procedure that eliminates pain and has been found to be successful in various studies (28).

However, according to data in the literature, it seems that the most effective and long-lasting surgical method is microvascular decompression of the trigeminal nerve root, although the mechanisms for this still remain unclear (29). In TN, vascular compression of the trigeminal nerve root seems to be the main cause of pain, but sclerotic plaques can also be responsible for the disease. In most cases, these surgical treatments relieve pain significantly and create important relief for the patient.

CONCLUSIONS

TN causes neuropathic pain (usually unilateral) that can be induced by low-intensity mechanical insults, and which may last for seconds to minutes. The cause of this pain is due to the loss of the myelin sheath of Schwann cells, which makes the nerve vulnerable (A β fibers) and causes the axon to become sensitive and hyperexcitable. Drug therapy usually involves the use of carbamazepine, a sodium channel blocker that is also used for seizures, bipolar disorder, and epilepsy. When pharmacological therapy does not work, a surgical course is suggested, such as microvascular decompression, percutaneous ganglion lesions and gamma knife radiosurgery. With TN, the main goal is to alleviate the severe pain and improve the patient's quality of life.

Conflict of interest

The authors declare that they have no conflict of interest.

REFERENCES

1. Bendtsen L, Zakrzewska JM, Heinskou TB, et al. Advances in diagnosis, classification, pathophysiology, and management of trigeminal neuralgia. *The Lancet Neurology*. 2020;19(9):784-796. doi:[https://doi.org/10.1016/s1474-4422\(20\)30233-7](https://doi.org/10.1016/s1474-4422(20)30233-7)
2. Parascandolo E, Levinson K, Rizzoli P, Sharon R. Efficacy of Erenumab in the Treatment of Trigeminal Neuralgia. *Neurology: Clinical Practice*. 2021;11(3):227-231. doi:<https://doi.org/10.1212/cpj.0000000000001075>
3. Araya EI, Claudino RF, Piovesan EJ, Chichorro JG. Trigeminal Neuralgia: Basic and Clinical Aspects. *Current Neuropharmacology*. 2020;18(2):109-119. doi:<https://doi.org/10.2174/1570159x17666191010094350>
4. Pihut M, Szuta M, Ferendiuk E, Zeńczak-Więckiewicz D. Differential Diagnostics of Pain in the Course of Trigeminal Neuralgia and Temporomandibular Joint Dysfunction. *BioMed Research International*. 2014;2014. doi:<https://doi.org/10.1155/2014/563786>
5. Chen Q, Yi DI, Perez JNJ, et al. The Molecular Basis and Pathophysiology of Trigeminal Neuralgia. *International Journal of Molecular Sciences*. 2022;23(7):3604. doi:<https://doi.org/10.3390/ijms23073604>
6. Svedung Wettervik T, Snel D, Kristiansson P, Ericson H, Abu Hamdeh S. Incidence of trigeminal neuralgia: A population-based study in Central Sweden. *European Journal of Pain*. 2023;27(5):580-587. doi:<https://doi.org/10.1002/ejp.2081>
7. Leclercq D, Thiebaut JB, Héran F. Trigeminal neuralgia. *Diagnostic and Interventional Imaging*. 2013;94(10):993-1001. doi:<https://doi.org/10.1016/j.diii.2013.08.002>
8. Gambeta E, Chichorro JG, Zamponi GW. Trigeminal neuralgia: An overview from pathophysiology to pharmacological treatments. *Molecular Pain*. 2020;16:174480692090189. doi:<https://doi.org/10.1177/1744806920901890>
9. Yuan J, Gong L, Wu H, et al. Case report of primary Sjögren Syndrome with simple trigeminal lesion as initial symptom. *Journal of neuroimmunology (Print)*. 2018;324:126-128. doi:<https://doi.org/10.1016/j.jneuroim.2018.08.005>
10. Xu M, Liu J, Zhang H, Li R, Wei J. Trigeminal Ganglion Electrical Stimulation for Trigeminal Nerve Postherpetic Neuralgia: A Retrospective Study. *Journal of pain research*. 2023;Volume 16:3633-3641. doi:<https://doi.org/10.2147/jpr.s432842>
11. Liao JY, Zhou TH, Chen BK, Liu ZX. Schwann cells and trigeminal neuralgia. *Molecular Pain*. 2020;16:174480692096380. doi:<https://doi.org/10.1177/1744806920963809>
12. Peker S, Kurtkaya Ö, Üzün İ, Pamir MN. Microanatomy of the Central Myelin-Peripheral Myelin Transition Zone of the Trigeminal Nerve. *Neurosurgery*. 2006;59(2):354-359. doi:<https://doi.org/10.1227/01.neu.0000223501.27220.69>
13. Cruccu G, Agostino R, Inghilleri M, Manfredi M, de Visser O. The masseter inhibitory reflex is evoked by innocuous stimuli and mediated by A beta afferent fibres. *Experimental brain research*. 1989;77(2):447-450. doi:<https://doi.org/10.1007/bf00275005>
14. Gualdani R, Gailly P, Yuan JH, et al. A TRPM7 mutation linked to familial trigeminal neuralgia: Omega current and hyperexcitability of trigeminal ganglion neurons. *Proceedings of the National Academy of Sciences of the United States of America*. 2022;119(38). doi:<https://doi.org/10.1073/pnas.2119630119>
15. Jeon HJ, Han SR, Park MK, Yang KY, Bae YC, Ahn DK. A novel trigeminal neuropathic pain model: Compression of the trigeminal nerve root produces prolonged nociception in rats. *Progress in Neuro-Psychopharmacology and Biological Psychiatry*. 2012;38(2):149-158. doi:<https://doi.org/10.1016/j.pnpbp.2012.03.002>
16. Maarbjerg S, Di Stefano G, Bendtsen L, Cruccu G. Trigeminal neuralgia – diagnosis and treatment. *Cephalalgia*. 2017;37(7):648-657. doi:<https://doi.org/10.1177/0333102416687280>
17. Besson G, Danangeth Y. [Neurologic diagnosis and therapy of headaches]. *Revue de stomatologie et de chirurgie maxillo-faciale*. 2000;101(3):119-128.

18. Ang L, Kim HJ, Heo JW, et al. Acupuncture for the treatment of trigeminal neuralgia: A systematic review and meta-analysis. *Complementary Therapies in Clinical Practice*. 2023;52:101763. doi:<https://doi.org/10.1016/j.ctcp.2023.101763>
19. Miccoli G, Cicala D, Spennato P, Imperato A, Ruggiero C, Cinalli G. Cavum trigeminale cephalocele associated with intracranial hypertension in an 18-month-old child: illustrative case. *Journal of Neurosurgery Case Lessons*. 2021;1(22). doi:<https://doi.org/10.3171/case21136>
20. Moreau N, Dieb W, Descroix V, Svensson P, Ernberg M, Boucher Y. Topical Review: Potential Use of Botulinum Toxin in the Management of Painful Posttraumatic Trigeminal Neuropathy. *Journal of Oral & Facial Pain and Headache*. 2017;31(1):7-18. doi:<https://doi.org/10.11607/ofph.1753>
21. Yuan S, Wang N, Yao Y, et al. Role of 5-HT_{2A} Receptor in Modulating Glutamatergic Activity in the Ventrolateral Orbital Cortex: Implication in Trigeminal Neuralgia. *Neuroscience*. 2022;502:107-116. doi:<https://doi.org/10.1016/j.neuroscience.2022.08.018>
22. Qin H, Cai J, Yang FS. Could calcitonin be a useful therapeutic agent for trigeminal neuralgia? *Medical Hypotheses*. 2008;71(1). doi:<https://doi.org/10.1016/j.mehy.2008.01.018>
23. Acevedo-González JC, Taub-Krivoy A. Modification to the Hartel Route Radiofrequency Technique for the Treatment of Trigeminal Neuralgia: A Technical Note. *World Neurosurgery*. 2023;178:14-19. doi:<https://doi.org/10.1016/j.wneu.2023.06.112>
24. Yadav Y, Nishtha Y, Sonjjay P, Vijay P, Shailendra R, Yatin K. Trigeminal neuralgia. *Asian Journal of Neurosurgery*. 2017;12(4):585. doi:https://doi.org/10.4103/ajns.ajns_67_14
25. Cruccu G, Finnerup NB, Jensen TS, et al. Trigeminal neuralgia: New classification and diagnostic grading for practice and research. *Neurology*. 2016;87(2):220-228. doi:<https://doi.org/10.1212/wnl.0000000000002840>
26. Zakrzewska JM, Linskey ME. Trigeminal neuralgia. *BMJ clinical evidence*. 2014;2014:1207. Published 2014 Oct 6.
27. Wang Z, Wang Z, Li K, Su X, Du C, Tian Y. Radiofrequency thermocoagulation for the treatment of trigeminal neuralgia. *Experimental and Therapeutic Medicine*. 2021;23(1). doi:<https://doi.org/10.3892/etm.2021.10939>
28. Wolf A, Kondziolka D. Gamma Knife Surgery in Trigeminal Neuralgia. *Neurosurgery clinics of North America*. 2016;27(3):297-304. doi:<https://doi.org/10.1016/j.nec.2016.02.006>
29. Niazi F, Elkaim LM, Zadeh Khomami NM, et al. Microvascular Decompression and Trigeminal Neuralgia: Patient Sentiment Analysis Using Natural Language Processing. *World neurosurgery*. 2023;180:e528-e536. doi:<https://doi.org/10.1016/j.wneu.2023.09.107>