



Review

PATIENTS WITH TMD IN DEVELOPMENTAL AGE AND CORRELATION WITH MALOCCLUSIONS: A TRANSVERSAL PILOT STUDY

M. Macri¹, F. Festa¹, M.S. Mancarella² and P. Caccianiga^{3*}

¹Department of Innovative Technologies in Medicine & Dentistry, University “G. D’Annunzio” of Chieti-Pescara, Chieti, Italy; ²Private practitioner, Milan, Italy;

³School of Medicine and Surgery, University of Milano-Bicocca, Monza, Italy

*Correspondence to:

Paolo Caccianiga, DDS

School of Medicine and Surgery, University of Milano-Bicocca,

Via Cadore 48, 20900 Monza, Italy

e-mail: p.caccianiga@campi.unimib.it

ABSTRACT

This study investigated the prevalence of different symptoms and signs in a population of children and adolescents with temporomandibular disorders (TMD) by evaluating the correlation with occlusal variables. TMD signs and symptoms were recorded in 40 subjects (age range 5-15 years), divided into two groups: 20 subjects treated in Chieti (Italy) and 20 in Murcia (Spain). Once the Angle dental class was identified, it was recorded for each patient the signs and/or symptoms of T.M.J. dysfunctions and occlusal interferences. The percentages of signs and symptoms were compared using the χ^2 -test to determine the differences among the groups for the rates of TMD symptoms, bruxism, joint sounds, deviation during the opening, reduced opening/lateral/protrusive movements, malocclusions, and myofascial pain. There is no statistically significant difference between the two groups ($\chi^2=2.849$, $p>0.05$), an indicator of the same racial origin. Subjects with first dental or skeletal class and deep bite showed a higher prevalence of TMD symptoms. According to literature, it is considered more linked to TMD problems with the deep bite rather than the first skeletal or dental class.

KEYWORDS: *temporomandibular disorders, orthodontics, malocclusion*

INTRODUCTION

There are five major causative factors associated with TMD: occlusion, trauma, emotional distress, deep nociceptive stimuli, and parafunctional activities (1). The importance of occlusal factors in TMDs is a critical topic in dentistry, and

Received: 16 August 2019

Accepted: 03 October 2019

ISSN: 2038-4106

Copyright © by BIOLIFE 2019

This publication and/or article is for individual use only and may not be further reproduced without written permission from the copyright holder. Unauthorized reproduction may result in financial and other penalties. **Disclosure: All authors report no conflicts of interest relevant to this article.**

there is no overwhelming evidence for or against the hypotheses of significant correlation or of null role in etiology.

The parafunctional activity, which includes clenching or grinding the teeth, can be responsible for the onset of TMD symptoms; during the day, oral habits such as biting the cheeks or the tongue, sucking a finger, nibbling pencils, pins, holding an object under the chin, are often performed unconsciously; on the other hand, during single sleep episodes (clenching) or rhythmic contractions (bruxism) may occur, certainly related to emotional stress, probably also to a genetic predisposition or to C.N.S. disorders. However, parafunctional activity may not be the primary cause of TMD symptoms but a factor that maintains or accentuates the symptoms: in this case, both the primary etiological agent and the parafunction must be treated to achieve complete remission of symptoms. Bruxism is a very common phenomenon in children, with a prevalence between 20 and 38%, but it is self-limiting, without significant symptoms, and tends to brux in adulthood.

According to the study by Pullinger et al., four occlusal aspects occurred more frequently in subjects with TMD, and they are a skeletal anterior open bite, slipping greater than 2 mm between intercuspation position and retruded contact position, overjet greater than 4 mm, and 5 or more missing posterior teeth. (1, 2). Deviations greater than 3 mm are more important risk factors for TMDs, while small discrepancies between 1 and 3 mm are epidemiologically normal. (3-7).

Acute or unexpected changes in the occlusion could induce symptoms of TMD due to the important influence on the chewing muscles; the parafunctional activities, different from the functional ones, instead of being inhibited by the contact of the teeth, seemed to be caused by them. So, perfect occlusion is the basis of healthy muscle function, and occlusion disorders can lead to increased muscle tone (co-contraction) and symptoms. The signs of TMDs are muscle pain, joint pain, joint noises, and limited mandibular range of motion.

Some clinicians suggest that deep bites, cross bites, and double bites are predisposing factors. Other factors such as trauma, emotional stress, bruxism, and some systemic conditions can favor the development of a T.M.J. disorder.

The opportunity to start orthodontic therapies at an early age is increasingly accepted with fixed, orthopedic, or mobile devices. During orthodontic treatment, pharmacological agents (nonsteroidal anti-inflammatory drugs and topical anesthetic formulations) have been generally recommended by dentists to get pain relief (8, 9). Nonpharmacological methods also exist, such as vibratory stimuli, transcutaneous nerve stimulation, and low-level laser therapy (LLLT) (10-11-12, 13). These findings confirm previous research on the efficacy of LLLT in controlling pain during orthodontic treatment; in fact, intraoral administration of LLLT significantly enhances the orthodontic treatment to achieve dental alignment; it produces dental movement with reduced time of wearing, minimum of 12 hours per day (14, 15).

In another study, it was found that patients with teeth erupted in an ectopic position get benefit from the use of LLLT and self-ligating orthodontic appliance with the formation of new keratinized gingiva, about 2,7 mm, 0.45 per month (16).

Epidemiology

Temporo-mandibular disorders (TMD) are one of the most common causes of orofacial pain after dental pain, and there is a peak incidence between 20 and 40 years of age, with a higher prevalence in women.

The authors of a study on children in primary dentition reported that the prevalence of TMD signs and/or symptoms was 34%, and the prevalence of joint click was 2.7% in primary dentition, 10.1% in late mixed dentition, and 16.6% in permanent teething (17, 18). Xie, Lin et al. investigated a group of Chinese students from 1979 to 2017 and reported a 29.1% TMD prevalence and joint noise as the most frequent sign (19). According to previous studies in European countries, TMD prevalence rates were 26.5% in Poland (Loster et al., 2015) and 22.58% in Italy, slightly lower than the rate observed in China (20-22). In contrast, higher prevalence rates appeared in the Middle East and South American countries: 34.9% in Brazil, 34.7% in Iran, and 46.8% in Riyadh (Saudi Arabia) (22-25). This discrepancy could be related to race, different economies, war, and eating habits.

It is generally accepted that T.M.J. disorders have a multifactorial etiology, and one of these factors is the occlusal condition, although it is still a debated topic in the literature.

In the Oral, Medical, and Biotechnological Sciences Department of the G. D'Annunzio University of Chieti-Pescara, we carried out a study to establish the prevalence of T.M.J. dysfunctions in developmental age and to assess the relationship with malocclusions. Subsequently, a comparison was made with the data collected at the Clinica Universitaria Odontologica of Murcia (Spain).

MATERIALS AND METHODS

A total of 40 patients were selected, 20 from the University G. D'Annunzio, Chieti-Pescara and 20 from "Clinica Universitaria Odontologica", Universidad de Murcia (Spain).

The following inclusion criteria were used for subject participation in the study: 1. age between 5 to 15 years old, 2. orthodontic treatment according to well-defined malocclusion.

Patients were excluded if they had a history of polyarthritis, muscle spasms, neurological or psychiatric disorders, vascular diseases, genetic syndromes, cleft lip, abnormalities of the palate, craniofacial syndromes, or PBM therapy for TMD pain.

The occlusal assessment was made considering Angle malocclusion classification, myofascial pain in various body areas (head, neck, shoulders, back) measured with the VAS, T.M.J. sounds and bruxism, flawed habits, such as onychophagy or atypical swallowing, then the overjet, the overbite, the facial symmetry, the dental crowding, the deviation during the opening, the reduced opening, lateral, and protrusive movements and finally the chosen orthodontic treatment. The examination for TMD signs and symptoms was based on the standardized Research Diagnostic Criteria for Temporomandibular Disorders (25). Muscles were digitally palpated to assess muscle tenderness and pain.

Photos and radiographic examinations of each patient are viewed at the beginning and end of the treatment is finished. All the patients underwent regular routine and orthodontic clinical checks. The data collected in Chieti Clinic were then compared with those ones collected in the Murcia Clinic, calculating the statistical value chi-square. As for the statistical analysis, the chi-square test was used to compare the two percentages obtained in the study and to evaluate the existing statistical significance or to verify whether the difference between the two values is due to chance or not. Everything is calculated at the 5% probability level, considering 1 degree of freedom and n equal to 40.

RESULTS

In this study, about Chieti data, 16 patients have bruxism and/or clenching, 7 patients have class I, 9 patients have Class II, and 8 patients have Class III (Table Ia).

Only one patient, aged 11 years, has a noticeable joint click on the right and left, sometimes in an opening on the right side; he has a first molar class on the right side and a second molar class on the left side. It also reports back pain in the lower back, neck pain, and headache, with pain 8-9 (VAS) in the temples and in the T.M.J. About myofascial pain, it was found that in 12 patients, the pterygoid muscle palpation is painful, and in 10, the Temporalis Tendon palpation, in 6 patients, the sternocleidomastoid palpation, and in 3 patients, the masseter one.

The intraoral examination revealed that 11 patients have a deep bite (range 4-7 mm), 3 an open bite, 5 a posterior cross-bite, 3 an anterior cross-bite, and 3 have a deviation during the opening with a displacement of the lower midline. As for the overjet, 6 patients have an increased O.J. (range 3-11 mm) and 1 decreased (with a value of -5 mm). Three patients also have crowding, 1 has atypical swallowing, and 1 has low lingual posture. Depending on the problem, patients are treated with Frankel devices of type I, II, III, and V (with base 3), RPE, or Multibrackets.

According to data from the University Hospital of Murcia, 13 patients have a first molar and/or skeletal class, 9 patients a second molar and/or skeletal class, and 6 patients have a third molar and/or skeletal class (Table Ib). 5 patients have bruxism and/or clenching, 2 painless joint noise and 2 joint noise with pain. As for malocclusions, 4 patients have a mono/bilateral posterior cross-bite and 2 anterior cross-bite; 9 patients have atypical swallowing, 2 onychophagy, 7 have a mandibular deviation in the opening, 9 an increased overjet (range 3-6.5 mm), 5 patients have an open bite and 4 have oral respiration and/or lingual interposition between the teeth.

The chi-square value (1, n = 40) is 2,849 and the p-value is .091431, so the difference between the two groups isn't statistically significant at the 5% probability level ($p > 0.05$). The results of the χ^2 test revealed that there is a greater correlation between the first molar and/or skeletal class and a sign/symptom of TMD. Considering the cases in which there is a clinically evident articular noise, we notice that in 3 out of 5 cases, there is a posterior cross-bite, and in 2 out of 5 cases, a mandibular deviation in the opening.

Table Ia. *Classification of patients.*

Patient	Age	ID	Disorders TMJ	VAS	Palpation	Intraoral exam	Treatment
1 TC	13	SC	no	no	Pterygoids, tt, scm, masseter	OB closed 3 mm	FR II
2 VP	12	SC	clenching		tt, pt, scm	2 class, I, OB closed	FR V, 2
3 FM	9	SC	bruxism			2 class, I, OB closed	FR V, III
4 SD	13	TC	bruxism, chenching	headache	Tempolaris tendon		RPE
5 DC	12	FC, SC (canin right and left)	bruxism, chenching		Trapezes, medial pterygoid	OB open 1 mm, super space 5mm, crowding lower 2 mm, deviation right side 2 mm	FR II
6 AD	11	TC		Headache 2-3 times/month	SCM, TT, medial and lateral pterygoids	Dev left 2 mm, OJ 0 mm	FR III
7 GT	8	II mol e canin, I division SC	bruxism, chenching			OB cloded, dev left	FR V, base 3
8 IC	9	FC	clenching	headache		OJ 3 mm, CB post left	FR V, 3
9 VP	11	TC	clenching		Masseter, TT, medial and lateral pterygoids	OB open	FR V, 5 shields
10 AD	15	FC mol, TC canin, II division	clenching			OB closed, OJ 1 mm, midline right 2 mm, crowding upper 2 mm, lower 6-7 mm	brackets

11 N S	8	TC	clenching		SCM, pterygoids	CB 5 mm ant, concave profile, wide lower arch, Spee reverse, low lingual posture, OJ 5 mm, dev right	RPE
12 S A	10	FC	Clenching, strong bruxism			OB closed	FR II
13 F B	11	FC mol, TC r and I canin	clenching		pterygoids	OB closed, OJ 2 mm, atypical swallowing, crowding	FR III
14 G D	12	TC mol and can		Neck ache	SCM, upper trapeze	CB ant and post, OB open	RPE + FR III
15 M F	11	SC mol	Clenching, bruxism	Yes, VAS 3-4, SCM pain		OJ 6 mm	FR II, structure 5
16 I P	12	SC	clenching	Random headache due tu study, pulsating right side	TT, lateral pterygoids	CB post, convex profile, OB closed 4-5mm, OJ 2-3 mm	FR 5 + RPE
17 M M	11	PC mol left, TC mol right, TC can right + SC left	clenching		Lateral pterygoids, masseter, TT, upper trapeze	OB closed 7 mm	FR 3
18 V A	11	FC mol right, SC mol left	Click both sides, opening on right side sometimes, clenching with attrition, bruxism	Neckache, backache, lumbar, headache, pain 8 temples and 9 TMJ right	TT, pterygoids	CB post, OB closed 4 mm, OJ 2-3 mm	RPE + FR I
19 S B	13	SC, I division	clenching	Shoulder and frontal pain (10)	TT, medial pterygoid	OB closed 5 mm, OJ 8 mm	FR 5, base 3
20 S C	8	TC mol and can, I division		Frontal pain: 6	SCM, TT, pterygoids, supra and suborbital	CB post right, incompetent lips, OB open	RPE + FR III

Table Ia. *Classification of patients.*

Patient	Age	ID	Disorders TMJ	VAS	Palpation	Intraoral exam	Treatment
1 M M	11	FC molar				Posterior bilateral cross bite, premature contact, no deviation	Hyrax appliance + lingual arch
2 N G	11	SC mol left, FC mol right				OJ 3 mm, deviation right, atypical swallowing	Lingual arch + Hawley plaque
3 M R	14	FC mola, SC skeletal				OJ 4 mm, onyophagy, oral breathing, OB 1/3	multibrackets
4 J P	13	TC skeletal, FC molar	Left articular noise with pain			OJ 1 mm, deviation (S at the opening), atypical swallowing, open bite, posterior bilateral cross bite	Hyrax appliance + Hawley plaque + speech therapist
5 R B	14	FC molar, SC scan				OJ 2.5 mm, OB 2/3	Twin block + brackets
6 C C	11	Molar left FC, TC molar right TC, FC skeletal	Left articular noise with pain, bruxism and cleching				Quad-helix without arms + brackets
7 M M	8	SC mol and can, SC skeletal				Atypical swallowing	McNamara for maxillary disjunction + Hawley plaque + speech therapist
8 D M	10	FC skeletal, SC mol and can				Opening left deviation	Quad-helix without arms + brackets

9 MT	8	TC mol and can, TC skeletal				OJ 2 mm, atypical swallowing, open bite, posterior right cross bite, maxillary retrognathia	Maxillary disjunction with McNamara + facial mask
10 AT	12	TC mol and can				Anterior cross bite	brackets
11 SS	11	SC skeletal, FC mol and can				Anterior cross bite, OJ 2.5 mm, Atypical swallowing, reduced airways	McNamara + transpalatine bar
12 JF	12	SC mol incomplete right, FC mol left				Atypical swallowing, OJ 6.5 mm right-left, opening deviation	Quad-helix without arms + brackets
13 IF	10	FC mol and can, TC skeletal	Articular noise, bruxism and cleching			OJ 2.5 mm, atypical swallowing, lingual interposition	Hawley plaque, McNamara + multibrackets
14 LT	9	FC, TC can	clenching			OB 1 mm	FR I
15 AS	14	SC skeletal, SC mol and can	bruxism			OJ 4 mm, atypical swallowing	Brackets + Hyrax
16 PH	13	SC skeletal, FC mol				OJ 5.5 mm, atypical swallowing, right deviation 1 mm	Multibrackets
17 IN	8	SC skeletal, FC can				OJ 0.5 mm, opening deviation (does "S"), oral breathing, atypical swallowing	McNamara + Hawley plaque + lingual arch

18 C F	14	FC skeletal, SC mol and can	Articular noise			OJ 4 mm, oral breathing, bilateral posterior cross bite	Multibrackets
19 E H	7	FC skeletal, mol and can	Bruxism			Atypical swallowing, onychophagy, right deviation 2 mm	Multibrackets
20 S C	8	TC molar and canin				Posterior right cross bite, incompetent lips, open bite	RPE + multibrackets

Considering the cases of bruxism and/or clenching, in 6 cases out of 22, there is also a mandibular deviation to the right or left, in 7 cases, the palpation of the temporalis tendon is painful, in 11 cases, there is a deep bite, in 4 cases an anterior or posterior cross-bite and in other 4 cases an overjet increased in a range from 4 to 11 mm.

The patients are treated, according to the problem, with Hyrax appliance, lingual arch, Hawley plaque, Twin-block, Multibrackets, Quad-helix, Mc Namara for maxillary disjunction, Frankel I, transpalatine bar, and face mask. Therapy with the speech therapist is also often associated.

Correlating the molar class, the overbite, and the orthodontic treatment with the TMD and parafunctions result that in the first class, there is a higher prevalence of TMD and of parafunctions, that more patients with normo and deep bite have TMD while more patients with open bite have parafunctions (Table IIa-c). Finally, there is a higher prevalence of TMD in treatments with mobile devices and of parafunctions in interceptive treatment with R.E.P./maxillary disjunctor.

Table II. Correlation between the molar class, the overbite, and the orthodontic treatment with the TMD.

a.

	TMD	Parafunctions
I class	11/40 patients	10/40 patients
II class	10/40 patients	8/40 patients
III class	6/40 patients	8/40 patients

b.

	TMD	Parafunctions
Normo-bite	10/40 patients	2/40 patients
Deep bite	10/40 patients	1/40 patients
Open bite	3/40 patients	5/40 patients

c.

	TMD	Parafunctions
Interceptive treatment with REP/maxillary disjunctor	7/40 patients	8/40 patients
Treatment with mobile appliances	16/40 patients	6/40 patients
Fixed treatment	6/40 patients	7/40 patients

DISCUSSION

Some clinicians suggest that occlusal conditions such as deep bites, cross bites, and double bites are predisposing factors; other factors such as trauma, emotional stress, bruxism, and some systemic conditions may also be responsible for the development of TMD. Angle's second class, cross-bite, and instability in maximum intercuspation have been associated with higher chances of having a TMD (26, 27). The authors of two studies concluded that there was no relationship between dental classification and TMD, as Akeel and AlJasser also believe; they found no significant association between signs or symptoms of IOTN (Index of Orthodontic Treatment Need) and TMD. (28, 29). However, most authors assessing the features of malocclusions reported that the open bite, the deep bite, and the posterior cross-bite seemed to be most associated with TMD (30, 31). Runge et al. concluded that a wide interincisal angle and an increased overbite were associated with joint noises (32). In contrast, Sadowsky et al. found no significant connection between joint noise and functional occlusion (33). In 4 other studies, no connection was found between TMD and malocclusion (30). A higher TMD prevalence was observed in patients over 18 years in most studies (34, 35).

In the study conducted at the University of Cairo, there was a greater relationship between TMD cases and the first molar class rather than the second or third ones (36). Furthermore, in the cross-sectional study conducted by De Paiva Bertoli et al., the association between anxiety, malocclusion, and TMD prevalence was studied. Adolescents with high anxiety had a prevalence of TMD symptoms 4.06 times greater, while adolescents with moderate anxiety levels had a prevalence of TMD symptoms 1.94 times greater, regardless of gender (37).

Karibe et al. found a significant association between advanced head position, daytime clenching, night grinding of teeth, and TMD in adolescents (38). Thilander and Bilgiç (2017) found a significant association between Class III and TMD (39, 40). It has been stated that an altered occlusion can cause disorders in oral function and also psychosocial problems due to the dentofacial aesthetic compromise; a high prevalence of malocclusions has been reported in children and adolescents, ranging from 39 to 93%.

A significant association was found between TMD pain and negative O.V.B. in the cross-sectional study by Perrotta, Bucci, and Simeon in 2019 (41). There was a statistically significant association also between TMD pain and unilateral cross-bite, such as between TMD pain and bilateral cross-bite. In the sample studied (700 children aged 9 to 11 years), the high frequency of parafunctions was significantly associated with TMD pain. In the study of Tecco, Nota et al. emerges that the TMD signs and/or symptoms were 1.6 times more frequent in subjects with Class II/first division than subjects in Class I, as well as joint noises (2.75 times more frequent). For myalgia, females had a higher prevalence (1.96 times) and were statistically significant than males (42).

Finally, the study by Tecco S., Macri M., Polimeni A., & Festa, F. demonstrated a higher prevalence of myofascial pain among subjects aged between 12 and 15 years compared to those aged 5 to 11 years and also a higher prevalence in the female sex (21). In addition, TMD signs and symptoms and reduced functional movements were found more frequently in subjects with unilateral posterior cross-bite than in subjects with anterior or posterior bilateral cross-bite.

In the Rinchuse study comparing various systematic reviews, few associations were established between malocclusion or functional occlusion and TMD signs and symptoms. The only positive relationship that emerged was 1) between the number of crowded posterior teeth and the subjective symptoms of dysfunction and 2) between abrasions and clinical dysfunctions. Puberty has been associated with more pain conditions, such as headache, abdominal pain, and musculoskeletal pain, and it is conceivable that puberty development and related hormonal, physical, and psychosocial changes could influence the genesis, onset, and/or the maintenance of temporomandibular disorders (TMD) (43).

In the systematic review of Song, the association between TMD and pubertal development is studied, and the prevalence of temporomandibular pain (of the masticatory muscles and/or the A.T.M.) increases with the advancement of pubertal development; in fact, it affected

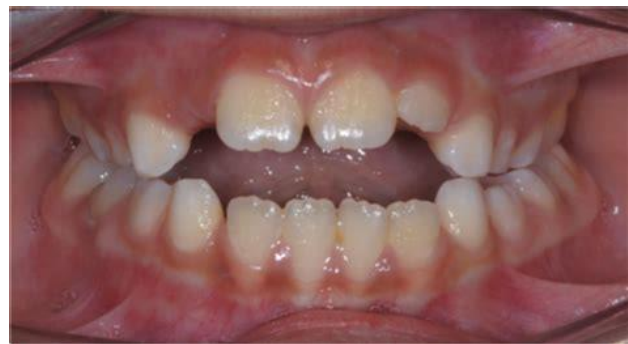

Fig. 1. *Interdental brushes in action.*

about 4% in pre-pubertal subjects and 14% in subjects who had completed pubertal development (44, 45) (Fig. 1, 2).

CONCLUSION

The results in the current study indicate that the prevalence of temporomandibular dysfunctions is 80% in Chieti patients and 55% in Murcia patients, considering joint clicks, the presence of bruxism, and/or clenching and opening deviation as pathognomonic signs. The chi-square value (1, n = 40) obtained is equal to 2,849, and the p-value is .091431; therefore, the difference between the two groups is not statistically significant at the 5% probability level ($p > 0.05$).

We observed a significant association between TMD and deep bite, considering the occlusal interferences, and also between the first molar and/or skeletal class, considering malocclusions.

Finally, we can conclude that very often, in the presence of joint noise and tooth-grinding and/or bruxism, there is also a mandibular deviation in the opening.

Author contributions

M.M. and F.F. designed the research study. M.S.M. performed the research. M.S.M. and P.C. wrote the manuscript. All authors contributed to editorial changes in the manuscript. All authors read and approved the final manuscript.

Funding

This research received no external funding.

Conflict of Interest

The authors declare no conflict of interest.

REFERENCES

1. Magee KR. Bruxism related to levodopa therapy. *JAMA*. 1970;214(1):147. <https://pubmed.ncbi.nlm.nih.gov/5469056/>
2. Brandon S. Unusual effect of fenfluramine. *British Medical Journal*. 1969;4(5682):557-558. doi:10.1136/bmj.4.5682.557-c
3. Hartmann E. Alcohol and Bruxism. *New England Journal of Medicine*. 1979;301(6):333-334. doi:10.1056/nejm197908093010621
4. Clark GT, Tsukiyama Y, Baba K, Watanabe T. Sixty-eight years of experimental occlusal interference studies: What have we learned? *The Journal of Prosthetic Dentistry*. 1999;82(6):704-713. doi:10.1016/s0022-3913(99)70012-0
5. Cacchiotti DA, Plesh O, Bianchi P, McNeill C. Signs and symptoms in samples with and without temporomandibular disorders. *Journal of Craniomandibular Disorders: Facial & Oral Pain*. 1991;5(3):167-172. <https://pubmed.ncbi.nlm.nih.gov/1812144/>
6. Dworkin SF, Huggins KH, LeResche L, et al. Epidemiology of Signs and Symptoms in Temporomandibular Disorders: Clinical Signs in Cases and Controls. *The Journal of the American Dental Association*. 1990;120(3):273-281. doi:10.14219/jada.archive.1990.0043
7. Stringert HG, Worms FW. Variations in skeletal and dental patterns in patients with structural and functional alterations of the temporomandibular joint: A preliminary report. *American Journal of Orthodontics*. 1986;89(4):285-297. doi:10.1016/0002-9416(86)90050-3
8. Isola G, Perillo L, Migliorati M, et al. The impact of temporomandibular joint arthritis on functional disability and global health in patients with juvenile idiopathic arthritis. *European Journal of Orthodontics*. 2018;41(2):117-124. doi:10.1093/ejo/cjy034
9. Marie SS, Powers M, Sheridan JJ. Vibratory stimulation as a method of reducing pain after orthodontic appliance adjustment. *Journal of clinical orthodontics: J.C.O.* 2003;37(4):205-208; quiz 203-204. <https://pubmed.ncbi.nlm.nih.gov/12747073/>
10. Roth PM, Thrash WJ. Effect of transcutaneous electrical nerve stimulation for controlling pain associated with orthodontic

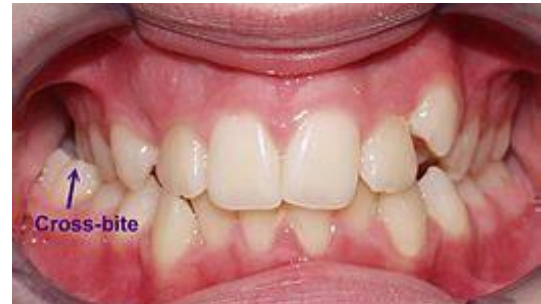

Fig. 2. Cross-bite.

- tooth movement. *American Journal of Orthodontics and Dentofacial Orthopedics*. 1986;90(2):132-138. doi:10.1016/0889-5406(86)90045-4
11. Sousa MVS, Pinzan A, Consolaro A, Henriques JFC, de Freitas MR. Systematic literature review: influence of low-level laser on orthodontic movement and pain control in humans. *Photomedicine and Laser Surgery*. 2014;32(11):592-599. doi:10.1089/pho.2014.3789
 12. Rigoldi Bonjardim L, Duarte Gavião MB, Grammatico Carmagnani F, Jose Pereira L, Midori Castelo P. Signs and symptoms of temporomandibular joint dysfunction in children with primary dentition. *Journal of Clinical Pediatric Dentistry*. 2004;28(1):53-58. doi:10.17796/jcpd.28.1.0772w75g91963670
 13. Lo Giudice A, Nucera R, Perillo L, Paiusco A, Caccianiga G. Is Low-Level Laser Therapy an Effective Method to Alleviate Pain Induced by Active Orthodontic Alignment Archwire? A Randomized Clinical Trial. *Journal of Evidence Based Dental Practice*. 2019;19(1):71-78. doi:10.1016/j.jebdp.2018.11.001
 14. Lo Giudice A, Nucera R, Matarese G, et al. analysis of resistance to sliding expressed during first order correction with conventional and self-ligating brackets: an in-vitro study. *International Journal of Clinical and Experimental Medicine*. 2016;9(8):15575-15581.
 15. Caccianiga G, Paiusco A, Perillo L, et al. Does Low-Level Laser Therapy Enhance the Efficiency of Orthodontic Dental Alignment? Results from a Randomized Pilot Study. *Photomedicine and Laser Surgery*. 2017;35(8):421-426. doi:10.1089/pho.2016.4215
 16. Caccianiga G, Crestale C, Cozzani M, et al. Low-level laser therapy and invisible removal aligners. *Journal of Biological Regulators and Homeostatic Agents*. 2016;30(2 Suppl 1):107-113. <https://pubmed.ncbi.nlm.nih.gov/27469556/>
 17. Caccianiga G, Stanizzi A, Zorzella P, Crestale C, Denotti D, Squarzoni N. Laser Biostimulation and Self Ligating Appliances in Orthodontics: Periodontal Remodeling. *European Journal of Inflammation*. 2012;10(2_suppl):55-59. doi:10.1177/1721727x120100s211
 18. Gomes MF, Goulart M da GV, Giannasi LC, et al. Effects of the photobiomodulation using different energy densities on the periodontal tissues under orthodontic force in rats with type 2 diabetes mellitus. *Brazilian Oral Research*. 2018;32(0). doi:<https://doi.org/10.1590/1807-3107bor-2018.vol32.0061>
 19. Thilander B, Rubio G, Pena L, de Mayorga C. Prevalence of Temporomandibular Dysfunction and Its Association With Malocclusion in Children and Adolescents: An Epidemiologic Study Related to Specified Stages of Dental Development. *The Angle Orthodontist*. 2002;72(2):146-154.
 20. Xie C, Lin M, Yang H, Ren A. Prevalence of temporomandibular disorders and its clinical signs in Chinese students, 1979–2017: A systematic review and meta-analysis. *Oral Diseases*. 2019;25(7):1697-1706. doi:10.1111/odi.13016
 21. Loster JE, Osiewicz MA, Groch M, Ryniewicz W, Wieczorek A. The Prevalence of TMD in Polish Young Adults. *Journal of Prosthodontics*. 2015;26(4):284-288. doi:10.1111/jopr.12414
 22. Tecco S, Crincoli V, Di Bisceglie B, et al. Signs and Symptoms of Temporomandibular Joint Disorders in Caucasian Children and Adolescents. *CRANIO®*. 2011;29(1):71-79. doi:10.1179/crn.2011.010
 23. Bertoli FM de P, Bruzamolín CD, Pizzatto E, Losso EM, Brancher JA, de Souza JF. Prevalence of diagnosed temporomandibular disorders: A cross-sectional study in Brazilian adolescents. Milgrom PM, ed. *PLOS ONE*. 2018;13(2):e0192254. doi:10.1371/journal.pone.0192254
 24. Ebrahimi M, Dashti H, Mehrabkhani M, Arghavani M, Daneshvar-Mozafari A. Temporomandibular Disorders and Related Factors in a Group of Iranian Adolescents: A Cross-sectional Survey. *Journal of Dental Research, Dental Clinics, Dental Prospects*. 2011;5(4):123-127. doi:10.5681/joddd.2011.028
 25. Habib SR, Al Rifaiy MQ, Awan KH, Alsaif A, Alshalan A, Altokais Y. Prevalence and severity of temporomandibular disorders among university students in Riyadh. *The Saudi Dental Journal*. 2015;27(3):125-130. doi:10.1016/j.sdentj.2014.11.009
 26. Dworkin SF, LeResche L. Research diagnostic criteria for temporomandibular disorders: review, criteria, examinations and specifications, critique. *Journal of Craniomandibular Disorders: Facial & Oral Pain*. 1992;6(4):301-355. <https://pubmed.ncbi.nlm.nih.gov/1298767/>
 27. Selaimen CMP, Jeronymo JCM, Brilhante DP, Lima EM, Grossi PK, Grossi ML. Occlusal Risk Factors for Temporomandibular Disorders. *The Angle Orthodontist*. 2007;77(3):471-477. doi:10.2319/0003-3219(2007)077(0471:orfftd)2.0.co;2

28. Marklund S, Wänman A. Risk factors associated with incidence and persistence of signs and symptoms of temporomandibular disorders. *Acta Odontologica Scandinavica*. 2010;68(5):289-299. doi:10.3109/00016357.2010.494621
29. Slade GD, Sanders AE, Bair E, et al. Preclinical episodes of orofacial pain symptoms and their association with health care behaviors in the OPPERA prospective cohort study. *Pain*. 2013;154(5):750-760. doi:10.1016/j.pain.2013.01.014
30. Jain S, Chourse S, Jain D. Prevalence and Severity of Temporomandibular Disorders among the Orthodontic Patients Using Fonseca's Questionnaire. *Contemporary Clinical Dentistry*. 2018;9(1):31-34. doi:10.4103/ccd.ccd_689_17
31. Olsson M, Lindqvist B. Mandibular function before and after orthodontic treatment. *The European Journal of Orthodontics*. 1995;17(3):205-214. doi:10.1093/ejo/17.3.205
32. Tanne K, Tanaka E, Sakuda M. Association between malocclusion and temporomandibular disorders in orthodontic patients before treatment. *J Orofac Pain*. 1993;7(2):156-162.
33. Runge ME, Sadowsky C, Sakols EI, BeGole EA. The relationship between temporomandibular joint sounds and malocclusion. *American Journal of Orthodontics and Dentofacial Orthopedics*. 1989;96(1):36-42. doi:10.1016/0889-5406(89)90226-6
34. Sadowsky C, Muhl ZF, Sakols EI, Sommerville JM. Temporomandibular Joint Sounds Related to Orthodontic Therapy. *Journal of Dental Research*. 1985;64(12):1392-1395. doi:10.1177/00220345850640121401
35. Yap AU, Dworkin SF, Chua EK, List T, Tan KB, Tan HH. Prevalence of temporomandibular disorder subtypes, psychologic distress, and psychosocial dysfunction in Asian patients. *J Orofac Pain*. 2003;17(1):21-28.
36. Yang PY, Su NY, Lu MY, Wei CY, Yu HC, Chang YC. Trends in the prevalence of diagnosed temporomandibular disorder from 2004 to 2013 using a Nationwide health insurance database in Taiwan. *Journal of Dental Sciences*. 2017;12(3):249-252. doi:10.1016/j.jds.2017.01.001
37. Aboalnaga A, Amer N, Elnahas M, et al. Malocclusion and Temporomandibular Disorders: Verification of the Controversy. *Journal of Oral & Facial Pain and Headache*. 2019;39(4):440-450. doi:10.11607/ofph.2260
38. de Paiva Bertoli FM, Bruzamolín CD, de Almeida Kranz GO, Lasso EM, Brancher JA, de Souza JF. Anxiety and malocclusion are associated with temporomandibular disorders in adolescents diagnosed by RDC/TMD. A cross-sectional study. *Journal of Oral Rehabilitation*. 2018;45(10):747-755. doi:10.1111/joor.12684
39. Karibe H, Shimazu K, Okamoto A, Kawakami T, Kato Y, Warita-Naoi S. Prevalence and association of self-reported anxiety, pain, and oral parafunctional habits with temporomandibular disorders in Japanese children and adolescents: a cross-sectional survey. *B.M.C. Oral Health*. 2015;15(1). doi:10.1186/1472-6831-15-8
40. Thilander B, Rubio G, Pena L, de Mayorga C. Prevalence of Temporomandibular Dysfunction and Its Association With Malocclusion in Children and Adolescents: An Epidemiologic Study Related to Specified Stages of Dental Development. *The Angle Orthodontist*. 2002;72(2):146-154. doi:10.1043/0003-3219(2002)072<0146:POTDAI>2.0.CO;2
41. Bilgiç F, Gelgör İE. Prevalence of Temporomandibular Dysfunction and its Association with Malocclusion in Children: An Epidemiologic Study. *Journal of Clinical Pediatric Dentistry*. 2017;41(2):161-165. doi:10.17796/1053-4628-41.2.161
42. Perrotta S, Bucci R, Simeon V, Martina S, Michelotti A, Valletta R. Prevalence of malocclusion, oral parafunctions and temporomandibular disorder-pain in Italian schoolchildren: An epidemiological study. *Journal of Oral Rehabilitation*. 2019;46(7). doi:10.1111/joor.12794
43. Tecco S, Nota A, Caruso S, et al. Temporomandibular clinical exploration in Italian adolescents. *CRANIO®*. 2017;37(2):77-84. doi:10.1080/08869634.2017.1391963
44. Rinchuse DJ, McMinn JT. Summary of evidence-based systematic reviews of temporomandibular disorders. *American Journal of Orthodontics and Dentofacial Orthopedics*. 2006;130(6):715-720. doi:10.1016/j.ajodo.2005.04.037
45. Song YL, Yap AU, Türp JC. Association between temporomandibular disorders and pubertal development: A systematic review. *Journal of Oral Rehabilitation*. 2018;45(12):1007-1015. doi:10.1111/joor.12704



Observational Study

LEDDERHOSE'S DISEASE

V. Sollazzo¹

¹Medical Center, Ferrara, Italy

Correspondence to:

Vincenzo Sollazzo, MD

Orthopedic Surgeon, Medical Director, Medical Center, Ferrara, Italy

e-mail: slv@unife.it

ABSTRACT

Ledderhose's disease (LD), also known as plantar fibromatosis, is a rare, highly proliferative condition of plantar aponeurosis that is clinically distinguished by nodules located particularly along the medial foot border. Dupuytren's sickness is histopathologically linked to it. Old age, alcoholism or nicotine misuse, liver problems, trauma or vibrations exposure, and autoimmune illnesses are some risk factors for this condition, although its specific cause is yet unknown. Despite being benign, the regional manifestations can be invasive, resulting in disabling deformities and toe contractures. Diagnostic techniques, including magnetic resonance imaging and ultrasound, are employed to ensure the diagnosis and rule out other illnesses. Conservative therapy is advised wherever practical. LD can be challenging to treat because of its high recurrence rate and requirement for numerous surgical procedures. From clinical symptoms to diagnostic techniques and conservative or operative treatment options, this study seeks to address this condition's significant components for daily medical practice.

KEYWORDS: *Ledderhose disease, hyperproliferation, plantar fibromatosis, foot*

INTRODUCTION

A kind of plantar fibromatosis called Ledderhose's disease (LD) is characterized by the development of hard, spherical, or flattening lumps (nodules) on the bottoms of the foot. Usually affecting both feet, it advances gradually but eventually gets better. Initially, the nodules are frequently harmless, but walking may become painful as they progress. LD patients may also have other disorders, including Dupuytren constriction, knuckle pads, and Peyronie disease, which are linked to the development of excessive fibrous tissue (1). In addition, numerous traumatic events, chronic alcohol use, chronic liver disease, hypertension, and seizures have also been linked to this syndrome. Although the precise origin of LD is unknown, inheritance is assumed to be a major factor in many instances. Comparatively, little has been written on LD since German physician Georg Ledderhose originally detailed his initial investigations of 50 cases in 1897. Dupuytren's

Received: 11 July 2019
Accepted: 28 August 2019

ISSN: 2038-4106

Copyright © by BIOLIFE 2019

This publication and/or article is for individual use only and may not be further reproduced without written permission from the copyright holder. Unauthorized reproduction may result in financial and other penalties. **Disclosure: All authors report no conflicts of interest relevant to this article.**

disease is the upper extremity equivalent of LD (2). However, more recent research has clarified this condition's clinical diagnosis and best care framework.

Despite being benign, plantar fibromatosis can have severe local symptoms that gradually replace the healthy aponeurosis, leading to pain, difficulty walking, balance issues, crippling contractures, and toe abnormalities. Nearly 25% of individuals may have a bilateral symptom (3, 4). Like plantar fasciitis, the middle fascia of the foot is where LD develops, making the nodules easily palpable (5, 6). Typically, the diagnosis has been established clinically and does not need to be verified. In order to distinguish between benign and malignant lesions (6), such as epithelium sarcoma (7), leiomyoma, rhabdomyosarcoma, and liposarcoma (8, 9), it may be necessary to perform an incisional biopsy with the histological investigation. The primary differential diagnoses are subcutaneous adipose necrosis, lipomas, keloids, desmoid cancers, ganglion cysts, and foreign-body reactions (9). Magnetic resonance imaging (MRI) has been successfully utilized to determine disease severity (10). In order to stop the course of LD and enhance the patient's quality of life, it is crucial to diagnose the condition quickly and develop a treatment plan. Usually, the initial diagnosis and the term medication may be quickly determined.

Epidemiology

LD's prevalence and causation are yet unknown (11). LD is an uncommon disease (12). Furthermore, numerous studies have revealed that this disorder has a detrimental impact on the quality of life for people affected and leads to severe functional disability. Although LD mainly affects people in their middle years, certain cases have been reported in children about 10 years old (13). Men are impacted more frequently than women (3). 25% of the time, bilateral illness is present (14). It frequently manifests concurrently with other appendages' hyperproliferative fibromatosis, such as Dupuytren's disease in the hands, Peyronie's disease in the penis, or keloid development. Frozen shoulder, alcoholism, diabetes, seizures, smoking, recurrent trauma, and protracted phenobarbital usage are other related disorders (14).

Diagnosis and clinical presentation

LD's medial or center plantar aponeurosis contains a slow-growing, 0.5–3.0 cm nodule (15). Since these nodules often do not damage the skin or smooth muscle tissue, they rarely cause palmar fascia contractions typical of Dupuytren's illness (15, 16). The great toe, however, has been documented to contracture in some cases, along with significant nodule invasion and proliferation (17). The patient's capacity to bear weight may be affected by symptoms such as pressure applied and distention, painful nodules, or sensitive, erythematous sores (18). A slow-growing mass along the longitudinal arch is the main symptom that most patients report. While the lump is initially harmless, as it grows, it becomes painful. One's discomfort may be made worse by wearing constricting shoes, applying pressure directly to the mass, and walking for extended periods. Over time, several fibromas may form and may be a factor in symptoms getting worse (15, 18).

The value of a physical examination cannot be overstated in identifying plantar fascia fibromatosis. A visual examination of the foot is necessary for the practitioner to detect swelling, damage to the skin, bruises, or deformity. Bony prominences must be felt with tendinous implantations along the foot and midfoot. It is important to take notice of any Achilles tendon or gastrocnemius contracture, as these conditions might exacerbate symptoms. It is necessary to record the patient's heel motion along with the patient's gait. Tarsal tunnel syndrome, plantar fasciitis, and calcaneal stress fracture must all be included in the differential diagnosis. The pathognomonic sign of fibromatosis is the development of one or more distinct lesions along the plantar fascia.

Histology

Histopathological and immunohistochemistry (IHC) analyses are used to confirm the diagnosis in the presence of specific clinical and radiographic symptoms (19). A microscopic and IHC investigation demonstrates that LD and Dupuytren's disease share several features (20). This condition is hypercellular, with a particular gain in the elastin component, unlike palmar fibromatosis. These cells feature a predominance of type III collagen, oval-shaped nuclei with small nucleoli, fine chromatin, and no discernible mitosis (21). LD can be classified into three phases using histological characteristics. In the normal fibrous tissue of the plantar fascia, the first phase, known as the proliferation phase, is characterized by a typical multinodular proliferation of fat. Similar in size and structure, these cells contain extended blood arteries and collagen fibres

separating their bland nuclei from their small nucleoli (22). The plantar fascia has not yet undergone any apparent changes. Type III collagen fibres are mainly formed during the second phase, known as the active phase, which results in nodule formation. The fibroblast cells resemble smooth muscle cells because they contain a lot of myosin and actin microfilaments

(21). The third phase, known as the maturation or residual phase, is characterized by a decrease in the formation of collagen and myofibroblasts, thick collagen fibres, and cells with an abundance of endoplasmic reticulum and the Golgi apparatus (18). At this point, the tissues constrict, resulting in flexor contractures (14).

Treatment

According to the unique characteristics, the existence and severity of the symptoms, the stage of the pathological alterations, and whether it is the first manifestation or relapse, a variety of therapeutic approaches are available. As with any condition, the most crucial elements are pain relief, patient comfort, and the utilization of treatment approaches that do not exacerbate or activate underlying chronic diseases (23). One can choose between surgical operations and conservative therapy plans in current practice. Early in the course of the illness, when there is no pain, discomfort when walking, or balance issues, conservative therapy can be used. It should be understood that, in the absence of surgical intervention, a new increase in nodule size or further relapse will eventually occur. Offloading orthotics, which can be used in the early stages of the disease to reduce strain on the fascia and provide pain relief but do not entirely stop the lesion's progression, are the least invasive treatment option (24).

Systemic analgesics are advised throughout the sessions, just like in other pathologies (25). Shock therapy causes the lesion to lyse by increasing its vascularity on the one hand and directing trauma to the lesion on the other, triggering an intense healing response (26). Few studies back up the idea that radiotherapy is helpful in the early stages of slowing the spread of the disease and maintaining foot function. Therefore, it has long been utilized as a possible treatment for Dupuytren's disease.

The hormone estrogen has various effects on the body, one of which is to make some cell types more contractile.

Anti-estrogen therapy has been suggested as a treatment for LD because of this.

Anti-estrogen therapy shows potential as a conservative treatment for LD due to the declines in fibroblast proliferative activity and contracture rates. After receiving anti-estrogen therapy, 15%–20% of Dupuytren's patients had nodule size regression, and 25%–30% reported no additional increase in nodule growth, according to another study. Therefore, treating LD patients with anti-estrogens like tamoxifen may slow the disease's progression (17).

Studies have shown that when surgery is chosen as the treatment for LD, there is a 60% nodular recurrence rate (18, 27). A positive family history of LD, numerous nodules, and bilateral foot involvement all raise this risk (28). Other surgical concerns, in addition to the possibility of recurrence, include decreased wound healing, skin necrosis, uncomfortable scarring, nerve entrapment, and loss of arch height (14). Fibroma recurrence has been proposed to be treated with adjuvant radiation. Recurrence after excision is uncommon following adjuvant radiotherapy (29). These results are encouraging. However, the advantage of preventing recurrence must be weighed against radiation's severe but infrequent dangers, such as reduced foot function, impaired wound healing, lymphedema, severe fibrosis, fracture of the irradiated bone, and radiation-induced cancer (28).

CONCLUSION

Ledderhose disease is a hyperproliferative disorder with an unclear etiology and few determining circumstances. It can be diagnosed clinically, but different conditions must be ruled out with an MRI or US. Since the histological part of the diagnosis is non-specific, a histological analysis may be carried out to support it. Once the diagnosis has been made, picking the best course of action can be difficult because there is no causal therapy; instead, only symptomatic and functional treatments are offered. As numerous conventional conservative medicines and cutting-edge therapeutic methods have been researched with varying degrees of success, the best way to manage LD is still being developed. Traditional therapies continue to be first-line alternatives for symptomatic care given the benign nature of this illness; however, solid long-term studies supporting their usage are still lacking. Therefore, more investigation is required to choose the best therapy algorithm. Several surgical procedures are available for severe cases, but recurrence of the nodules is not unusual.

REFERENCES

1. Lee TH, Wapner KL, Hecht PJ. Plantar fibromatosis. *The Journal of Bone & Joint Surgery*. 1993;75(7):1080-1084. doi:10.2106/00004623-199307000-00016
2. Dürr HR, Krödel A, Trouillier H, Lienemann A, Refior HJ. Fibromatosis of the Plantar Fascia: Diagnosis and Indications For Surgical Treatment. *Foot & Ankle International*. 1999;20(1):13-17. doi:10.1177/107110079902000103
3. de Souza DF, Micaelo L, Cuzzi T, Ramos-E-Silva M. Ledderhose disease: an unusual presentation. *The Journal of Clinical Aesthetic Dermatology*. 2010;3(9):45-47.
4. Lui TH. Endoscopic Subtotal Fasciectomy of the Foot. *Arthroscopy Techniques*. 2016;5(6):e1387-e1393. doi:10.1016/j.eats.2016.08.005
5. Jeswani T, Morlese J, McNally EG. Getting to the heel of the problem: plantar fascia lesions. *Clinical Radiology*. 2009;64(9):931-939. doi:10.1016/j.crad.2009.02.020
6. Păun DL, Poiană C, Petriș R, et al. Multiple endocrine neoplasia type 2A: case report. *Chirurgia (Bucharest)*. 2013;108(6):900-903.
7. Enzinger FM. Epitheloid sarcoma. A sarcoma simulating a granuloma or a carcinoma. *Cancer*. 1970;26(5):1029-1041.
8. Motolese A, Mola F, Cherubino M, Giaccone M, Pellegatta I, Valdatta L. Squamous Cell Carcinoma and Ledderhose Disease. *The International Journal of Lower Extremity Wounds*. 2013;12(4):297-300. doi:10.1177/1534734613502044
9. Geavlete BF, Brînzea A, ChecheriȚă IA, et al. Carcinoma in situ of the urinary bladder - from pathology to narrow band imaging. *Romanian Journal of Morphology and Embryology*. 2015;56(3):1069-1076.
10. Omor Y, Dhaene B, Grijseels S, Alard S. Ledderhose Disease: Clinical, Radiological (Ultrasound and MRI), and Anatomopathological Findings. *Case Reports in Orthopedics*. 2015;2015:741461. doi:10.1155/2015/741461
11. Gudmundsson KG, Jónsson T, Arngrímsson R. Association of Morbus Ledderhose with Dupuytren's contracture. *Foot & Ankle International*. 2013;34(6):814-815. doi:10.1177/1071100713475352
12. Young JR, Sternbach S, Willinger M, Hutchinson ID, Rosenbaum AJ. The etiology, evaluation, and management of plantar fibromatosis. *Orthopedic Research and Reviews*. 2018;11:1-7. doi:10.2147/orr.s154289
13. Godette GA, O'Sullivan M, Menelaus MB. Plantar fibromatosis of the heel in children: a report of 14 cases. *Journal of Pediatric Orthopedics*. 1997;17(1):16-17.
14. Carroll P, Henshaw RM, Garwood C, Raspovic K, Kumar D. Plantar Fibromatosis: Pathophysiology, Surgical and Nonsurgical Therapies: An Evidence-Based Review. *Foot & Ankle Specialist*. 2018;11(2):168-176. doi:10.1177/1938640017751184
15. Espert M, Anderson MR, Baumhauer JF. Current Concepts Review: Plantar Fibromatosis. *Foot & Ankle International*. 2018;39(6):751-757. doi:10.1177/1071100718768051
16. English C, Coughlan R, Carey J, Bergin D. Plantar and palmar fibromatosis: characteristic imaging features and role of MRI in clinical management. *Rheumatology*. 2012;51(6):1134-1136. doi:10.1093/rheumatology/ker522
17. Yasui Y, Takao M, Miyamoto W, Matsushita T. Plantar fibromatosis with flexion contracture and valgus deformity of the great toe. *Journal of Orthopaedic Science*. 2016;21(3):395-398. doi:10.1016/j.jos.2015.06.003
18. Veith NT, Tschernig T, Histing T, Madry H. Plantar Fibromatosis—Topical Review. *Foot & Ankle International*. 2013;34(12):1742-1746. doi:10.1177/1071100713505535
19. Akdag O, Yildiran G, Karamese M, Tosun Z. Dupuytren-Like Contracture of the Foot: Ledderhose Disease. *The Surgery Journal*. 2016;02(03):e102-e104. doi:10.1055/s-0036-1593355
20. Zgonis T, Peter Jolly G, Polyzois V, Kanuck DM, Stamatis ED. Plantar fibromatosis. *Clinics in Podiatric Medicine and Surgery*. 2005;22(1):11-18. doi:10.1016/j.cpm.2004.08.002
21. de Palma L, Santucci A, Gigante A, Di Giulio A. Plantar Fibromatosis: An Immunohistochemical and Ultrastructural Study. *Foot & Ankle International*. 1999;20(4):253-257. doi:10.1177/107110079902000408
22. Farsetti P, Tudisco C, Caterini R, Bellocci M. Ledderhose's disease: case study with histologic and ultrastructural analysis. *Italian Journal of Orthopedics and Traumatology*. 1992;18(1):129-133.
23. Knobloch K, Vogt PM. High-energy focussed extracorporeal shockwave therapy reduces pain in plantar fibromatosis (Ledderhose's disease). *BMC Research Notes*. 2012;5(1):542. doi:10.1186/1756-0500-5-542
24. Marchalik D, Lipsky A, Petrov D, Harvell JD, Milgraum SS. Dermatologic Presentations of Orthopedic Pathologies. *American Journal of Clinical Dermatology*. 2012;13(5):293-310. doi:10.2165/11595880-000000000-00000

25. Barnes DE, Adedapo A, Allison K. The treatment of severe flexion contracture of the great toe in a patient with Ledderhose's disease. *Journal of Plastic, Reconstructive & Aesthetic Surgery*. 2009;62(1):102-104. doi:10.1016/j.bjps.2007.08.004
26. Grenfell S, Borg M. Radiotherapy in fascial fibromatosis: A case series, literature review and considerations for treatment of early-stage disease. *Journal of Medical Imaging and Radiation Oncology*. 2014;58(5):641-647. doi:10.1111/1754-9485.12178
27. van der Veer WM, Hamburg SM, de Gast A, Niessen FB. Recurrence of Plantar Fibromatosis after Plantar Fasciectomy: Single-Center Long-Term Results. *Plastic and Reconstructive Surgery*. 2008;122(2):486-491. doi:10.1097/prs.0b013e31817d61ab
28. Kadir HKA, Chandrasekar CR. Partial fasciectomy is a useful treatment option for symptomatic plantar fibromatosis. *The Foot*. 2017;31:31-34. doi:10.1016/j.foot.2017.02.002
29. de Bree E, Zoetmulder FAN, Keus RB, Peterse HL, van Coevorden F. Incidence and treatment of recurrent plantar fibromatosis by surgery and postoperative radiotherapy. *The American Journal of Surgery*. 2004;187(1):33-38. doi:10.1016/j.amjsurg.2002.11.002



Evaluation Study

HUMAN MESENCHYMAL STEM CELLS AND THEIR DIFFERENTIATION ON TITANIUM SURFACES: A PILOT STUDY

G. Caccianiga¹, A. Leonida¹ and P. Caccianiga^{1*}

¹School of Medicine and Surgery, University of Milano-Bicocca, Monza, Italy

**Correspondence to:*

Paolo Caccianiga, DDS

School of Medicine and Surgery, University of Milano-Bicocca, 20900 Monza, Italy

e-mail: p.caccianiga@campus.unimib.it

ABSTRACT

The aim of our study was to evaluate the properties of a laser-modified titanium surface, specifically the promotion of a faster differentiation of human Mesenchymal Stem Cells (hMSCs) into osteoblasts. Furthermore, we wanted to assess if the titanium alone could be a sufficient factor in the induction of the differentiation towards the osteogenic lineage. Methods: hMSCs from donors were cultured into dishes containing titanium disks presenting three different surfaces: machined (M), sandblasted (S), and laser-modified (L). In addition, two types of medium were used, one standard DMEM and one capable of inducing hMSC in osteoblasts. Evaluations of the degree of differentiation were made with Alizarin stein after 28, 38, 42, 49, 56, and 63 days. Results: No signs of differentiation were evident in the control group, while in the test group, statistically significant differentiation was evident since the fourth week. L and S surfaces showed similar values, higher than the M surface. Discussion: on the L surface, the differentiation peaked in the sixth week, while the other two surfaces reached the peak in the seventh week. After the peak, the differentiation showed a slow decrease for the L surface and a rapid decrease for the other two surfaces. Conclusion: Titanium alone cannot be considered enough to induce the differentiation of hMSCs into osteoblasts. Still, the L surface induced a faster differentiation of stem cells.

KEYWORDS: *mesenchymal, stem cell, differentiation, laser, surface*

INTRODUCTION

Osseointegration, in the case of native and grafted bone, is similar to the healing after a bone fracture, akin to body healing processes (1). Healing processes involve a series of specific and codified vascular and cellular events. These mechanisms begin with creating the blood clot by platelet and synthesizing a fibrin network that acts as a three-dimensional scaffold. At the same time, platelets emit growing factors that attract leukocytes and stem cells to clean the wound and regenerate tissue lost because of the damage. Depending on the injured tissue, stem cells can differentiate into different cell lines. (2). LLLT (low-level laser therapy) is applied in order to improve the activity of stem cells during bone

Received: 28 June 2019
Accepted: 12 September 2019

ISSN: 2038-4106

Copyright © by BIOLIFE 2019

This publication and/or article is for individual use only and may not be further reproduced without written permission from the copyright holder. Unauthorized reproduction may result in financial and other penalties. **Disclosure: All authors report no conflicts of interest relevant to this article.**

regeneration procedures (3, 4), even during the decontaminating surgical stages (5, 6).

When a titanium fixture is placed in the alveolar bone, the implant's stability is granted only by the cortical bone, named "primary stability". At a microscopic level, the bone around the screw is resorbed, the primary stability decreases and the platelet creates the fibrin scaffold in contact with the metal surface. When osseointegration proceeds without difficulties, stem cells from the healthy peripheral bone, proliferate and differentiate into the osteoblastic line around the implant surface. These new osteoblasts deposit bone matrix directly onto the screw, determining the secondary stability's growth. Between the second and fourth week after the implant insertion, the primary stability is decreased while the secondary stability has not reached a strength yet: for this reason, the most significant part of implanting failures occur during this time window (7-11).

Most contemporary studies aim to research new implant surfaces that could speed the proliferation of the stem cells into osteoblasts, which could speed up the growth of the secondary stability (12).

In this study, the first aim is to evaluate if titanium alone can sufficiently stimulate the differentiation of stem cells into osteoblasts. The secondary goal is to evaluate the degree of differentiation of stem cells *in vitro* on a laser-modified (L) surface as compared with a sandblasted (S) and a machined (M) surface. The third objective is to estimate the stability of the adhesion of differentiated stem cells on the laser-modified titanium surface.

MATERIALS AND METHODS

Isolation of the cells and culture

Mesenchymal stem cells (hMSCs) were collected from the heparinised marrow of a healthy subject that underwent marrow aspiration for an allogeneic transplant at San Gerardo Hospital (Monza, Italy). The Ethics Committee approved the study of the School of Medicine and Surgery at the Milano Bicocca University (protocol n. 11/17), derived from the approval of the Italian National Institute of Health (ISS), protocol 30 July 2007-0040488.

Mononuclear cells were isolated by centrifugation in a Ficoll-Hypaque gradient, suspended in an Eagle medium modified by Dulbecco with a low concentration of glucose (LG-DMEM; Euroclone, Milano, IT), containing 10% of bovine fetal serum (FBS; Hyclone, Logan, UT), L-glutamine 2mM, Penicillin 100U/ml, Streptomycin 100µg/ml, Fungizone 250µg/ml (Lonza, Verviers, Belgium), and placed onto culture dishes with a concentration of 2×10^5 cells/cm². hMSCs cultures were maintained at 37°C in a humidified atmosphere containing 5% CO₂, and the medium was changed twice a week. When cultures reached about 80% of confluence, the cells were washed twice with Dulbecco's phosphate buffered saline solution (PBS; Sigma-Aldrich, St. Louis, MO), detached with a 0.05% trypsin/EDTA solution (Lonza, Verviers, Belgium), used for the experiment by replating on 75 cm² culture dishes.

As depicted by the International Society of Cellular Therapy (13), cells adhered to plastic were positive for CD105, CD73, and CD90, negative for CD34 and CD45 and able to differentiate osteoblasts, adipocytes and chondrocytes.

Preparation of titanium disks

The disks used were grade 4 pure titanium, with a diameter of 6mm and a height of 2.5mm. The surfaces were processed as follows:

- machined (M);
- sandblasted (S) with Al₂O₃ with a grain of 100;
- treated with laser (L) with pores of 20 µm in diameter and 30µm in height (Fig. 1).

After the surface treatment, the sample was washed with a 3% surfactant solution, rinsed with ultrapure water and sterilised with β radiations. The laser system used for processing the disks is formed by a laser light source, a scanning head and the assembled disk support to maintain, place and move the device during the process. The laser generator is a DPSS (Diode Pumped Solid State) working under Q-switching (nanosecond pulse duration). The laser makes it possible to create a sequence of pores while the scanner moves through an appropriate synchronisation of speed and frequency of pulse.

Culture of stem cells of the titanium disks and osteogenic differentiation

The titanium disks were placed at the bottom of 24 plates, and the hMSCs were cultured in a 10000 cells/cm² density in LG-DMEM with an addition of 10% FBS. In order to evaluate the adhesive strength and capacity of differentiation,




Fig. 1. (a) Surface machined; (b) Surface sandblasted; (c) Surface laser.

three ways of processing the titanium surface were chosen: M, S and L surfaces.

The pre-admixture substances for the determination of the osteogenic medium were chosen according to the Pittenger et al. (14) protocol that in 1999 examined the power of differentiation of hMSCs, by defining the culture medium that could induce in vitro osteogenic differentiation. According to that study, hMSCs were cultivated in an inductive medium, consisting of LG-DMEM with an addition of 10% FBS, to which 100nM of dexamethasone, 10mM β - glycerophosphate and 0.05mM ascorbic acid 2-phosphate (Sigma-Aldrich, St. Louis, MO) (test group). hMSCs cultured with LG-DMEM with an addition of 10% FBS medium, without any inductive factor, were used as a control group.

Staining with Alizarin and quantity evaluation

Osteogenic differentiation was evaluated through staining with Alizarin Red at days 28, 38, 42, 49, 56 and 63 from the introduction. The colourant binds to the calcium ions in the mineralised matrix, turning it red.

The cells in the titanium surface were rinsed with PBS and fixed with 4% paraformaldehyde for 10 minutes. After this, the cells were washed with double-distilled water and incubated in a solution containing Alizarin Red (Sigma-Aldrich, St. Louis, MO) and 1% ammonium hydroxide for 30 minutes at room temperature under stirring. After incubation, titanium disks were washed twice with double-distilled water, dried and photographed. For the quantitative evaluation of osteogenic differentiation, the colouring was quantified using a spectrophotometer (A405) after solution annealing with 0.5M HCl sodium dodecyl sulphate (15).

Statistical Analysis

Evaluation results were collected in a tabular form and underwent a statistical analysis with a T-test with a confidence interval of 95% ($p > 0.05$).

RESULTS

During the 28th day, the differentiation was evaluated utilising Alizarin Red staining of cells settled on titanium disks in the osteogenic medium and on disks in the medium that did not contain any inductive factor (100nM dexamethasone, 10mM β -glycerol sulphate and 0.05mM ascorbic acid 2-phosphate). The results of the absorbance values on the 28th day were initially compared with a T-test in pairs: the M surface in the inductive medium (IM) and the one in the not inductive medium (NIM); the L surface in the inductive medium (IL) and the same surface in the not inductive one (NIL). In these two comparisons, the values of p at 95% are all above 0.05, so they are statistically insignificant (Table I, II, III, IV). These results suggest that the osteogenic differentiation is not induced by the surface but by the culture medium (Table V and Fig. 2).

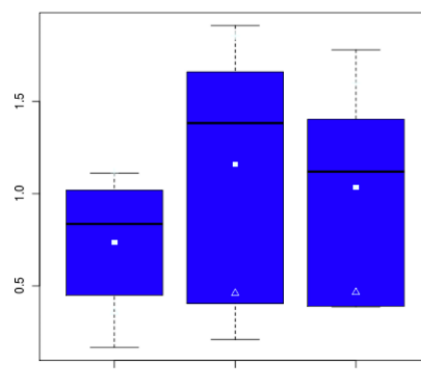


Fig. 2. Machined Driver (var1), Sandblasted Driver (var2) and Inducing Laser (var3) variables with minimum average and maximum 25th and 95th percentile.

The authors evaluated the differentiation progress after 28, 38, 42, 49, 56 and 63 days for all surfaces, and values are reported in Table VI. The behaviour of cells was similar for all three surfaces (Fig. 3): an increase in the differentiation took place during the first period (until the sixth or seventh week) but then a rapid decrease took place (until the ninth week). The laser-modified surface showed its differentiation peak after 42 days (Fig. 4), while the machined and sandblasted surfaces showed its differentiation peak after 49 days (Fig. 5 and 6). Moreover, the fall of the absorbance values for the laser-modified surface was slower than for the other two surfaces.

The values for the machined surface tended to zero, while the laser-modified and sandblasted surfaces tended to stabilise around a plateau corresponding to the absorbance value of 0.4.

DISCUSSION

Since our goal was to analyse cell differentiation and not the proliferation, the analysis started after the 28th day because Alizarin Red staining of the mineralised matrix became noticeable after 3-4 weeks of hMSC induction. We

Table I. Comparing the machined surface in the inductive medium (IM) and in the not inductive medium (NIM).

Variable Name	Estimated mean	Degrees of freedom	t	p	Confidence interval %	Confidence interval of difference
Var 1 (IM)	0,7361667	5,079224	4,532021	0,005980949	95	0,3056471
Var 4 (NIM)	0,03425					1,0988186

Table II. Comparing the laser modified surface in the inductive medium (IL) and in the not inductive one (NIL).

Variable Name	Estimated mean	Degrees of freedom	t	p	Confidence interval %	Confidence interval of difference
Var 3 (IL)	1,033167	5,080913	4,318875	0,007307405	95	0,4099526
Var 6 (NIL)	0,0275					1,601381

Table III. Comparing the machined surface in the inductive medium (IM) and the sandblasted surface in the inductive medium (IS).

Variable Name	Estimated mean	Degrees of freedom	t	p	Confidence interval %	Confidence interval of difference
Var 1 (IM)	0,7361667	7,697525	-1,303028	0,2301896	95	-1,174892
Var 2 (IS)	1,1585					0,3302249

Table IV. Comparing the machined surface in the inductive medium (IM) and the laser modified surface in the inductive medium (IL).

Variable Name	Estimated mean	Degrees of freedom	t	p	Confidence interval %	Confidence interval of difference
Var 1 (IM)	0,7361667	8,70032	-1,066284	0,3149887	95	-0,93404192
Var 3 (IL)	1,033167					0,3364192

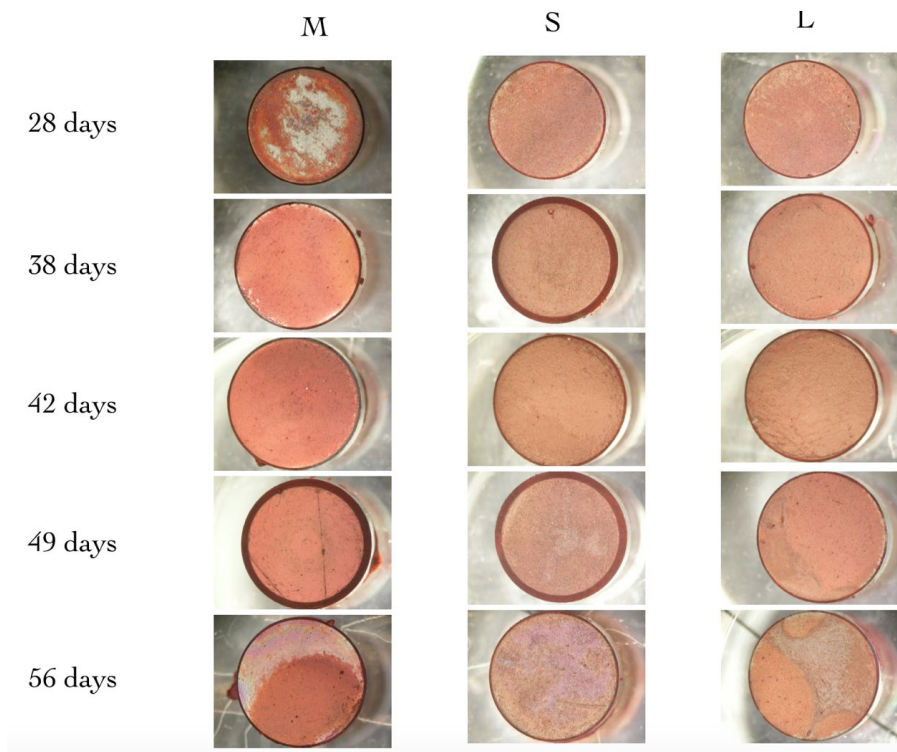


Fig. 3. Timeline of the cell behaviour on machined (M), sandblasted (S) and laser-treated (L) surfaces

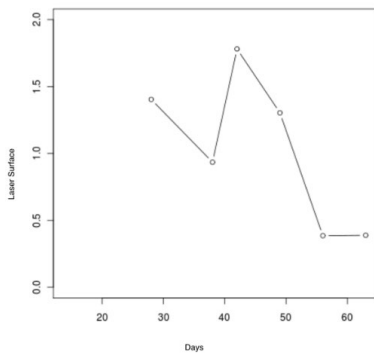


Fig. 4. The laser modified surface showed its differentiation peak after 42 days (Absorbance value index).

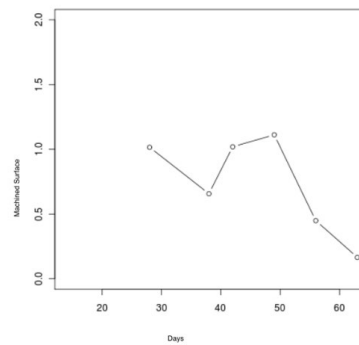


Fig. 5. The machined modified surface showed their differentiation peak after 49 days (Absorbance value index).

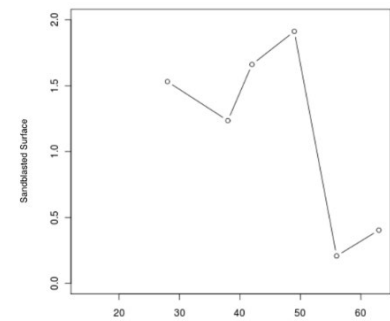


Fig. 6. The sandblasted modified surface showed a differentiation peak after 49 days (Absorbance value index).

Table V. Comparing of average, variance e standard deviation of absorbance for machined (IM), sandblasted (IS) and laser modified (IL) in medium with inductive and machined (NIM) in medium without inductive.

Variable Name	Mean	Variance	Sd
Var 1 (IM)	0,7361667	0,1427914	0,377867674
Var 2 (IS)	1,1585	0,4875195	0,698226
Var 3 (IL)	1,033167	0,3227070	0,568073
Var 4 (NIM)	0,03425	0,00075625	0,0275

decided not to analyse the enzymatic activity of alkaline phosphatase because this enzyme is a precocious indicator of differentiation, and we were interested in the differentiation over time.

The results showed a cellular detachment after the differentiation process, probably because of contact inhibition during growth. This fact led to a fall in absorbance (Table VI); this occurred prior to the laser-modified surface with respect to the other two sets of titanium disks. In L surfaces, the detachment appeared to be more gradual and stabilised on plateau level (absorbance value 0.4), similar to that observed in sandblasted surface; the detachment was almost complete for the machined surface.

All the surfaces were suitable to receive hMSC, which was then differentiated. hMSC grew and differentiated similarly regardless of the kind of surface at the end of the observation time (63 days); this confirms why titanium is the material primarily biocompatible in implantology (15,16).

If it is true that all the surfaces are suitable to receive hMSC, which subsequently differentiates, it is also true that the laser-modified and sandblasted surfaces in an osteogenic medium show a high grade of differentiation compared to the machined surface; this means that the modification of the implantation surfaces significantly impacts the adhesion and differentiation of hMSC and, consequently, the development of secondary stability (17-19).

Regarding the secondary stability, the differentiation peak for all the surfaces happened between the 42nd and the 49th day; this is reflected in the literature's description of the osseointegration process (17). The difference among machined, sandblasted, and laser-modified surfaces are that the differentiation peak is reached at different times, on the 42nd day for the laser-modified surface and the 49th day for the other two surfaces.

CONCLUSION

Titanium alone cannot be considered an inductive material to induce osteogenic differentiation of human mesenchymal stem cells. In our study, the inductive medium was necessary to obtain hMSC differentiation. However, modified surfaces can increase the differentiation speed of stem cells; this can be translated, from a clinical point of view, in an earlier secondary stability phase. It is also confirmed by the decrease of differentiation that is slower on the laser-modified surface (absorbance value plateau around 0.4). Compared to sandblasted and machined surfaces, this reaction can be seen as a better binding affinity between osteoblasts and treated titanium.

Since the behavior of modified surfaces could be very different in the human body, so in vivo studies are needed to better understand these biological processes.

Author Contributions

GC designed the research study; GC and AL performed the research; AL and PC wrote the manuscript. All authors contributed to editorial changes and approved the final manuscript. The authors declare no conflict of interest.

Table VI. Progression of the differentiation after 28, 38, 42, 49, 56 and 63 days for all the surfaces (Absorbance value index).

	M	S	L
28 days	0,657	1,235	0,935
38 days	1,015	1,531	1,404
42 days	1,019	1,661	1,781
49 days	1,112	1,912	1,304
56 days	0,449	0,208	0,386
63 days	0,165	0,404	0,389

REFERENCES

1. Vetter A, Epari DR, Seidel R, et al. Temporal tissue patterns in bone healing of sheep. *Journal of Orthopaedic Research*. 2010;28(11):1440-1447. doi:10.1002/jor.21175
2. Kuznetsov SA, Krebsbach PH, Satomura K, et al. Single-colony derived strains of human marrow stromal fibroblasts form bone after transplantation in vivo. *Journal of Bone and Mineral Research*. 1997;12(9):1335-1347. doi:10.1359/jbmr.1997.12.9.1335
3. Caccianiga G, Cambini A, Donzelli E, Baldoni M, Rey G, Paiusco A. Effects of laser biostimulation on the epithelial tissue for keratinised layer differentiation: an in vitro study. *Journal of Biological Regulators and Homeostatic Agents*. 2016;30(2 Suppl 1):99-105.
4. Leonida A, Paiusco A, Rossi G, Carini F, Baldoni M, Caccianiga G. Effects of low-level laser irradiation on proliferation and osteoblastic differentiation of human mesenchymal stem cells seeded on a three-dimensional biomatrix: in vitro pilot study. *Lasers in Medical Science*. 2012;28(1):125-132. doi:10.1007/s10103-012-1067-6
5. Caccianiga G, Rey G, Baldoni M, Paiusco A. Clinical, Radiographic and Microbiological Evaluation of High Level Laser Therapy, a New Photodynamic Therapy Protocol, in Peri-Implantitis Treatment; a Pilot Experience. *BioMed Research International*. 2016;2016:6321906. doi:10.1155/2016/6321906
6. Caccianiga G, Rey G, Fumagalli T, Cambini A, Denotti G, Giacomello MS. Photodynamic Therapy (Association Diode Laser/ Hydrogen Peroxide): Evaluation of Bactericidal Effects on Periodontopathy Bacteria: An in Vitro Study. *European Journal of Inflammation*. 2012;10(2_suppl):101-106. doi:10.1177/1721727x120100s220
7. Sbordone L, Sbordone C, Filice N, Menchini-Fabris G, Baldoni M, Toti P. Gene clustering analysis in human osseous remodeling. *Journal of Periodontology*. 2009;80(12):1998-2009. doi:10.1902/jop.2009.090290
8. Friedenstien AJ. Precursor cells of mechanocytes. *International Review of Cytology*. 1976;47:327-359. doi:10.1016/s0074-7696(08)60092-3
9. Raghavendra S, Wood MC, Taylor TD. Early wound healing around endosseous implants: a review of the literature. *The International Journal of Oral & Maxillofacial Implants*. 2005;20(3):425-431.
10. Dominici M, Le Blanc K, Mueller I, et al. Minimal criteria for defining multipotent mesenchymal stromal cells. The International Society for Cellular Therapy position statement. *Cytotherapy*. 2006;8(4):315-317. doi:10.1080/14653240600855905
11. Trisi P, Berardini M, Falco A, Vulpiani MP, Masciotra L. Effect of 50 to 60°C heating on osseointegration of dental implants in dense bone: an in vivo histological study. *Implant Dentistry*. 2014;23(5):516-521. doi:10.1097/ID.0000000000000162
12. Traini T, Danza M, Altavilla R, et al. Histomorphometric evaluation of an implant retrieved from human maxilla after 13 years. *International Journal of Immunopathology and Pharmacology*. 2011;24(2 Suppl):25-30. doi:10.1177/03946320110240S206
13. Horwitz EM, Le Blanc K, Dominici M, et al. Clarification of the nomenclature for MSC: The International Society for Cellular Therapy position statement. *Cytotherapy*. 2005;7(5):393-395. doi:10.1080/14653240500319234
14. Pittenger MF, Mackay AM, Beck SC, et al. Multilineage potential of adult human mesenchymal stem cells. *Science*. 1999;284(5411):143-147. doi:10.1126/science.284.5411.143
15. Stiehler M, Lind M, Mygind T, et al. Morphology, proliferation, and osteogenic differentiation of mesenchymal stem cells cultured on titanium, tantalum, and chromium surfaces. *Journal of Biomedical Materials Research*. 2008;86A(2):448-458. doi:10.1002/jbm.a.31602
16. Myllymaa S, Kaivosoja E, Myllymaa K, et al. Adhesion, spreading and osteogenic differentiation of mesenchymal stem cells cultured on micropatterned amorphous diamond, titanium, tantalum and chromium coatings on silicon. *Journal of Materials Science: Materials in Medicine*. 2009;21(1):329-341. doi:10.1007/s10856-009-3836-8
17. Hayes J, Khan I, Archer C, Richards R. The role of surface microtopography in the modulation of osteoblast differentiation. *European Cells and Materials*. 2010;20:98-108. doi:10.22203/ecm.v020a09
18. Olivares-Navarrete R, Hyzy S, Hutton D, et al. Direct and Indirect Effects of Microstructured Titanium Substrates on the Induction of Mesenchymal Stem Cell Differentiation towards the Osteoblast Lineage. *Biomaterials*. 2010;31(10):2728. doi:10.1016/j.biomaterials.2009.12.029
19. Powell K. It's the ecology, stupid! *Nature*. 2005;435(7040):268-270. doi:10.1038/435268a



Letter to the Editor

EAGLE'S SYNDROME

D. Lauritano¹ and P. Carls²

¹Dental School, Milano-Bicocca University, Milan, Italy;

²Consultant, Oral-Maxillofacial Surgeon, 69 Banbury Road, Oxford, UK

Correspondence to:

Dorina Lauritano, DDS

Dental School, Milano-Bicocca University, Milan, Italy

e-mail: dorina.lauritano@unimib.it

KEYWORDS: *Styloid process, pain, pharynx, throat*

To the Editor

The morphological abnormality of the styloid process is the defining feature of Eagle's condition, which Eagle first described in 1949 (1). Adult Caucasians' styloid processes often measure 20–30 mm in length, while adults in Asian populations typically measure 15.4–18.8 mm. A styloid process is considered extended if it is at least 30 mm long (2). Dysphagia and recurring neck and throat pain that radiates into the ear make up the clinical picture. Bilateral or, more typically, unilateral symptoms are both possible.

An excessively lengthened styloid process with/without an anomalous direction and/or an osseous styloid ligament is associated with Eagle's syndrome. Cranio-facial suffering is secondary to irritation of the nearby neurovascular and muscular anatomical structures, and it matches glossopharyngeal neuralgia. According to a theory, the superior constrictor muscle could compress the glossopharyngeal nerve as it travels through, causing pain associated with the elongated styloid process. Internal carotid artery compression or kinking has only occasionally been reported (3). Horner syndrome may result from the styloid process compressing the sympathetic nerve fibres (4). Glossopharyngeal and trigeminal neuralgia, migraine, myofascial pain dysfunction syndrome, cluster headaches, temporal arteritis, cervical arthritis, tumours, pain from unerupted third molars, and loose or absent dentures should all be considered in the differential diagnosis (5).

Patients over 50 years old and women are more likely to have the illness. A clinical entity's mixed, non-specific symptoms, the lack of a clear aetiological connection, and the limited information about it frequently cause a delay in diagnosis. Clinical history, as well as physical examination, are helpful diagnostic techniques. During an intraoral inspection, a palpable extended styloid process may cause discomfort. Specialized equipment, experience, and the proper indication of radiological study are required for a diagnosis. Simple radiography of the skull might be enough to show the anatomical anomaly. The gold standard for visualizing the anatomically complicated styloid process is a CT of the head and neck, particularly a 3D-CT scan; this is due to the issues of concealed overlapping anatomy being avoided. Additionally, it emphasizes the styloid process's angle, which is important for the interactions between the nearby anatomical structures. There is some debate in the literature on the proportion of patients with an enlarged styloid apophysis who are asymptomatic upon radiologic testing (6).

Received: 03 October 2019
Accepted: 16 November 2019

ISSN: 2038-4106

Copyright © by BIOLIFE 2019

This publication and/or article is for individual use only and may not be further reproduced without written permission from the copyright holder. Unauthorized reproduction may result in financial and other penalties. **Disclosure: All authors report no conflicts of interest relevant to this article.**

Etiology

The cause of Eagle syndrome is a topic of discussion. Dr Watt Eagle postulated that the styloid process and the stylohyoid ligaments develop osteitis, periostitis, or tendonitis due to surgical trauma (tonsillectomy) or localized chronic irritation, leading to reactive, ossifying hyperplasia. Later, researchers put up the theory that, in the presence of a suitable traumatic or stressful experience, residual mesenchymal elements, also referred to as Reichert cartilage residues, can undergo osseous metaplasia. In 1962, Epifanio theorized that the ossification of the styloid process also correlated with endocrine abnormalities in menopausal women who also experienced the ossification of other ligaments throughout their bodies. According to some searches, individuals with end-stage renal illness who had aberrant vitamin D, phosphorus, and calcium metabolism also experienced heterotopic calcification, which led to the lengthening of the styloid process and the development of Eagle Syndrome. Finally, retrospective research conducted in 2015 by Sekerci revealed a connection between an elongated styloid process and the existence of an arcuate foramen. Data from 542 individuals with three-dimensional CT scans were used to derive the results (7).

Epidemiology

Since the discovery of Eagle Syndrome, various research has been conducted to ascertain the frequency and prevalence of this disorder. The disparity in the diagnostic standards used for radiologic imaging probably causes variation in the epidemiology of this illness. According to some, the acknowledged maximum length for a typical styloid process is 3 cm, with 2.5 cm being the acceptable minimum. According to some research, a stylohyoid length of more than 2.5 cm is considered abnormal radiologically. Because of this length's stronger connection with discomfort, several studies have considered lengths longer than 4.0 cm abnormal. Between 4% and 7.3% of cases of aberrant stylohyoid length have been reported. If the stylohyoid complex is considered, the incidence increases from 22% to 84%. Despite the significant prevalence of aberrant stylohyoid complexes, 4–10% of patients report discomfort when they have these abnormalities. Pain often manifests unilaterally, although stylohyoid abnormalities frequently occur bilaterally (7).

Diagnosis

A thorough physical examination and medical history are required to diagnose Eagle syndrome. By carefully intraoral palpating, inserting the index finger in the tonsillar fossa, and exerting light pressure, it must be easy to detect an extended styloid process. Diagnosis of an extended styloid process is most likely if pain can be palpated and is either localized to the ear, face, or head. Normal styloid processes are typically not perceptible. The tonsillar fossa can be injected with a local anaesthetic to relieve discomfort and serve as a diagnostic tool.

Imaging techniques such as lateral head and neck radiographs, panoramic radiographs, lateral-oblique mandibular plain film, etc., can be used to diagnose Eagle syndrome. Current norms with a threshold length of 3 cm on radiographs are considered aberrant. Plain radiographs are also among the modalities which are most frequently used. The overall length of the styloid process may best be seen in lateral images. However, anteroposterior scans are also necessary to identify bilateral participation and lateral deviation. In challenging circumstances, CT scans have been utilized to support the diagnosis. The precise spatial orientation of the styloid processes could be seen thanks to the 3-D reconstruction. Based on the imaging techniques, ossification of the stylohyoid ligament could have been completely ruled out (8).

The best approach for precise localization determination is spiral-CT with subsequent 3-D reconstruction. Additionally, barium swallow examinations might demonstrate a filling deficiency in the depression of the extended styloid process. Imaging shows that the styloid process has grown longer and is close to other important structures (9).

Pathophysiology

The neurovascular structures found in the retro styloid compartment were thought to be compressed and put under stress due to the tonsillectomy-induced scar tissue formation around the styloid apex. However, persons who have never had a tonsillectomy may potentially develop Eagle syndrome. The pathophysiology of pain in Eagle syndrome has been linked to several potential factors. According to the first theory, an extended styloid process compresses cranial nerves, most frequently the glossopharyngeal nerve, leading to neck and throat pain. A different scenario is where the styloid process compresses the internal carotid artery (10).

Numerous symptoms may develop, including brief ischemia episodes and sympathetic nerve compression anywhere along the artery. Even though Eagle syndrome's pain is duller and more persistent, it frequently resembles glossopharyngeal neuralgia. However, instances of severe, sporadic pain along the glossopharyngeal nerve's course have also been documented. In addition, reactive hyperplasia, as well as reactive metaplasia, also exist. These ideas link the elongation

to either excessive development of the styloid process or trauma-induced ossification of the stylohyoid ligament complex. As Eagle first reported, this phenomenon may explain the frequency of Eagle syndrome in individuals who have undergone tonsillectomy (11).

Other potential reasons include improper angulation linked to an excessively long styloid process that irritates nearby muscles or mucous membranes. Another potential cause could be stretching and fibrosis affecting the fifth, seventh, ninth, and tenth cranial nerves after a tonsillectomy. Finally, the symptoms can be a product of ageing as it happens naturally. As soft tissues lose elasticity with age, insertion tendinosis, a disorder that affects stylohyoid insertion, may result in pain along the glossopharyngeal nerve that resembles Eagle syndrome due to degenerative and inflammatory changes. This symptom is more appropriately referred to as a pseudo-stylohyoid syndrome to prevent confusion (12).

Conservative management

Surgical therapy or more effective conservative medicine management are commonly used to treat Eagle syndrome. First-line analgesics, like non-steroid anti-inflammatory drugs, which include injections, anticonvulsants, antidepressants, and manipulation, are categories of primary medical therapies used (13). A combination of medication for patients who decline surgery includes gabapentin, tianeptine, tramadol, and acetaminophen, along with local injections of 1 mg triamcinolone/mepivacaine have been reported to be successful. The symptoms could almost entirely disappear by adding a weekly stellate ganglion block to this regimen (14).

As a last-resort conservative measure, local injection of anaesthesia and dexamethasone has been beneficial. However, over time, these injections' effects wane. Despite cases of physical manipulation with manual transpharyngeal fracture, it has been advised against using these techniques since they put other structures like the carotid artery at risk (15).

Surgical intervention

The literature frequently argue that surgical intervention yields more conclusive results and long-lasting symptom alleviation. The intraoral and cervical methods of surgical management are commonly used. The tonsillectomy is the first step in the conventional intraoral technique; the tonsillar fossa is then palpated to locate the styloid process tip. The medial pterygoid and superior constrictor muscles are then dissected downward. The styloid point is then identified through blunt dissection. The ligamentous attachments to the styloid process are cut off once the periosteum has been dissected; the styloid tip is finally fractured using a rongeur tool and removed as close as possible. After that, the tonsillar fossa is stitched shut. While the lack of an external scar improves cosmesis, it prevents the styloid process from fully exposing. However, most of the time, it does allow for enough resection to relieve symptoms.

Infection and inadequate exposure to control bleeding are potential dangers of this intraoral technique, particularly in the event of a carotid injury. Additionally, there is a chance of developing post-operative airway oedema, making bilateral instances somewhat contraindicated (11).

With the proviso of a scar, an external cervical approach offers the best exposure. This method starts with an oblique incision at the mandibular angle and dissects the sternocleidomastoid muscle. The area between the parotid gland and the digastric muscle's posterior belly is then investigated. Finally, the styloid process is resected after subperiosteal dissection over it to conclude the dissection. Potential damage to the facial nerve's marginal mandibular branch is one of this method's worrisome concerns (11). In the end, various surgical procedures, each with its own advantages, are available to treat Eagle syndrome.

REFERENCES

1. Kawasaki M, Hatashima S, Matsuda T. Non-surgical therapy for bilateral glossopharyngeal neuralgia caused by Eagle's syndrome, diagnosed by three-dimensional computed tomography: a case report. *Journal of Anesthesia*. 2012;26(6):918-921. doi:10.1007/s00540-012-1437-z
2. Ceylan A, Köybaşıoğlu A, Celenk F, Yılmaz O, Uslu S. Surgical treatment of elongated styloid process: experience of 61 cases. *Skull Base*. 2008;18(5):289-295. doi:10.1055/s-0028-1086057
3. Radak D, Tanaskovic S, Kecmanovic V, Babic S, Popov P, Gajin P. Bilateral Eagle Syndrome with Associated Internal Carotid Artery Kinking and Significant Stenosis. *Annals of Vascular Surgery*. 2016;34:271.e15-18. doi:10.1016/j.avsg.2016.01.015
4. Chang CA, Lin T, Fung K, Sharma M, Fraser JA. Isolated Horner Syndrome From an Elongated Styloid Process (Eagle Syndrome). *Journal of Neuro-Ophthalmology: The Official Journal of the North American Neuro-Ophthalmology Society*. 2015;35(4):387-

389. doi:10.1097/WNO.0000000000000260
5. Costantinides F, Vidoni G, Tonni I, Bazzocchi G, Bodin C, Di Lenarda R. Orofacial pain induced by Eagle syndrome in an elderly patient with temporomandibular disorders - a case report. *Gerodontology*. 2016;33(3):428-431. doi:10.1111/ger.12160
 6. Kent DT, Rath TJ, Snyderman C. Conventional and 3-Dimensional Computerized Tomography in Eagle's Syndrome, Glossopharyngeal Neuralgia, and Asymptomatic Controls. *Otolaryngology-Head and Neck Surgery*. 2015;153(1):41-47. doi:10.1177/0194599815583047
 7. Badhey A, Jategaonkar A, Anglin Kovacs AJ, et al. Eagle syndrome: A comprehensive review. *Clinical Neurology and Neurosurgery*. 2017;159:34-38. doi:10.1016/j.clineuro.2017.04.021
 8. Kamal A, Nazir R, Usman M, Salam B, Sana F. Eagle syndrome; radiological evaluation and management. *JPMA The Journal of the Pakistan Medical Association*. 2014;64(11):1315-1317.
 9. Pokharel M, Karki S, Shrestha I, Shrestha B, Khanal K, Amatya R. Clinicoradiologic Evaluation of Eagle's Syndrome and its Management. *Kathmandu University Medical Journal*. 2015;11(4):305-309. doi:10.3126/kumj.v11i4.12527
 10. Costantinides F, Vidoni G, Bodin C, Di Lenarda R. Eagle's syndrome: signs and symptoms. *Cranio: The Journal of Craniomandibular Practice*. 2013;31(1):56-60. doi:10.1179/crn.2013.008
 11. Fusco DJ, Asteraki S, Spetzler RF. Eagle's syndrome: embryology, anatomy, and clinical management. *Acta Neurochirurgica*. 2012;154(7):1119-1126. doi:10.1007/s00701-012-1385-2
 12. Colby CC, Del Gaudio JM. Stylohyoid Complex Syndrome: A New Diagnostic Classification. *Archives of Otolaryngology-Head & Neck Surgery*. 2011;137(3):248-252. doi:10.1001/archoto.2011.25
 13. Piagkou M, Anagnostopoulou S, Kouladouros K, Piagkos G. Eagle's syndrome: A review of the literature. *Clinical Anatomy*. 2009;22(5):545-558. doi:10.1002/ca.20804
 14. Malik Y, Dar JA, Almadani AAR. Seizures with an atypical aetiology in an elderly patient: Eagle's syndrome--how does one treat it? *BMJ case reports*. 2015;2015:bcr2014206136. doi:10.1136/bcr-2014-206136
 15. Green BN, Browske LKM, Rosenthal CMD. Elongated Styloid Processes and Calcified Stylohyoid Ligaments in a Patient With Neck Pain: Implications for Manual Therapy Practice. *Journal of Chiropractic Medicine*. 2014;13(2):128-133. doi:10.1016/j.jcm.2014.06.006



Case report

NOVEL GBR DOME-TECHNIQUE AROUND THE IMPLANT: A CASE REPORT

L. Parma Benfenati

Private Practice, Ferrara, Italy

**Correspondence to:*

Lucrezia Parma Benfenati, DDS

Private practice

Corso della Giovecca, 155, 44121 Ferrara, Italy.

e-mail: lucrezia.parmabenfenati@hotmail.it

ABSTRACT

Space maintenance and neutralisation of soft tissue pressure are mandatory to accomplish the desired horizontal bone volume augmentation in Guided Bone Regeneration (GBR) procedure. Supporting materials, such as titanium reinforced non-resorbable membranes, titanium screws, titanium meshes and recently customised grids, have been proposed to overcome these problems. In this regard, resorbable material, such as polydioxanone suture (PDS II), may be beneficial to reduce morbidity and avoid the need for other non-resorbable materials and metallic structures removal, which increases surgical trauma and may have a negative impact on patient recovery.

This case report documents a “dome” system in GBR using a bone substitute and a resorbable collagen membrane during the implant placement. The surgical re-entry, planned as the second therapeutic phase for the healing abutment insertion, allows direct clinical visualisation of the results at the end of the healing process. The clinical and radiographic documentation has a 6-year follow-up.

KEYWORDS: *implant, GBR dome-technique, Guided Bone Regeneration, resorbable material*

INTRODUCTION

Oral rehabilitation of partially or totally edentulous patients with endosseous implants is now a widespread method capable of ensuring predictable and reliable long-term results (1, 2). However, the remodelling process that takes place after tooth removal may result in bone defects, which may, as a result, jeopardise the correct three-dimensional positioning of the implant and the biological and esthetic outcomes of the final implant-supported rehabilitation (3). For this reason, during implant placement, the clinician has to cope with unfavourable anatomical situations, such as insufficient vertical and/or horizontal bone size. In this regard, several bone augmentation procedures have been depicted, including the use of autogenous block grafts (4), ridge split techniques (5), distraction osteogenesis (6) and guided bone regeneration (GBR)

Received: 19 October 2019
Accepted: 05 December 2019

ISSN: 2038-4106

Copyright © by BIOLIFE 2019

This publication and/or article is for individual use only and may not be further reproduced without written permission from the copyright holder. Unauthorized reproduction may result in financial and other penalties. **Disclosure: All authors report no conflicts of interest relevant to this article.**

(7, 8) for the treatment of such clinical situations.

Clinical and histological studies and publications with authoritative scientific evidence support the predictability of the GBR technique. Osteopromotion, based on the exclusion of rapidly proliferating connective tissue cells from residual bony walls, which is accomplished by using barrier membranes, is the guided bone regeneration primary objective (9-12).

In this regard, from an in-depth review with a meta-analysis perspective of published works, to achieve success, the clinician must absolutely comply with the following two discriminating conditions: create and maintain a space below the membrane; achieve healing with perfect closure of the flaps protecting the blood clot for as long as necessary (9, 10).

The keywords guiding regenerative techniques are universally summarised: cell selectivity, maintenance of space and neutralisation of soft tissue pressure are mandatory to preserve blood clot protection (11).

Thus, residual bone architecture represents the first and crucial clinical prognostic factor impacting material and technique selection. GBR finds an excellent indication in cases of bony dehiscences or fenestrations. Highly indicated also in cases of “ridge repair” if the bone ridge thickness is less than 50% of the thickness of the implant to be placed (12). In 1995 the same authors published a technique for soft tissue reconstructive treatment in gingival recessions (13). This technique is further adopted in treating bony defects around implants (14). Resorbable support materials such as PDS II may provide stability to soft and hard tissues, and due to its high mechanical strength and slow degradation rate, approximately 180 days may represent an ideal material (15, 16). During the surgical phase, a resorbable suture thread, PDS II, is employed as a resorbable “dome” device to maintain space. Such a device, in case series, was able to create, below the membrane, adequate space and maintain appropriate blood clot protection, stabilising the wound in both a “1-stage” and 2-stage” GBR approach (13). The PDS II resorbable suture consists of a monofilament obtained by monomer paradioxanone polymerisation and is widely used in various medical and surgical fields. As reported in the literature, PDS II is slowly resorbed by a hydrolytic reaction, starting at day 91 and completed after 182 days, in vivo (14).

The “dome technique” may be a valuable solution, even minimally invasive, compared to other procedures, in an initial operative phase of implant placement when the bone thickness is reduced.

This case report describes the osseous reconstructive technique in treating a “non-space making” bony defect.

CASE REPORT

The 57-year-old patient, in good general health and a nonsmoker, presented with a left upper first premolar (element 2.4) edentulism, previously extracted due to fracture (Fig. 1). The first bicuspid area shows a concave architecture due to previous traumatic tooth loss. The existing implant replacing the second bicuspid presents an exposure of the prosthetic structure that did not create aesthetic discomfort to the patient. Moreover, the patient had never complained about the “long tooth” (Fig.1).

Thus, an initial surgical phase is planned for implant placement following CBCT radiographic investigation for three-dimensional evaluation of residual bone. An intrasulcular incision is executed, involving the implant elements in areas 2.6 and 2.5, continuing with a paramarginal vestibular intrasulcular incision in the canine. Next, a mesial 45° bevelled hockey-stick-shape release incision is made at 2.3 (Fig. 2).

A palatal incision at the base of the papillae allows both flaps to be raised to full thickness to visualise the bony ridge’s thickness better. (Fig. 2).

The vestibular flap is meticulously passivated with a periosteal

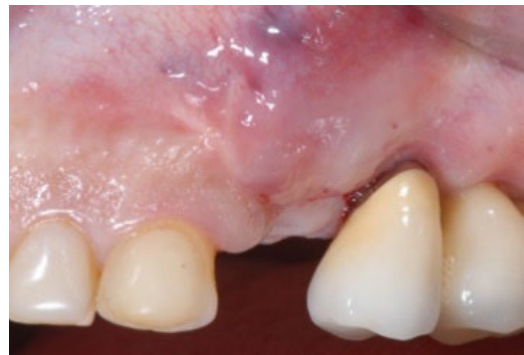

Fig. 1. Preoperative clinical condition in maxillary left lateral sextant.

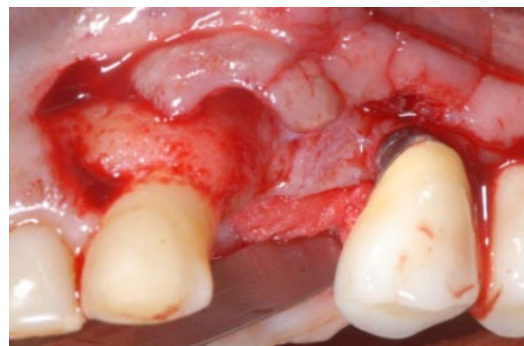

Fig. 2. Drawing and raising of the vestibular and palatal flaps with placement of sterile gauze in the palatine flap to assist the clinician in keeping it slightly apart.

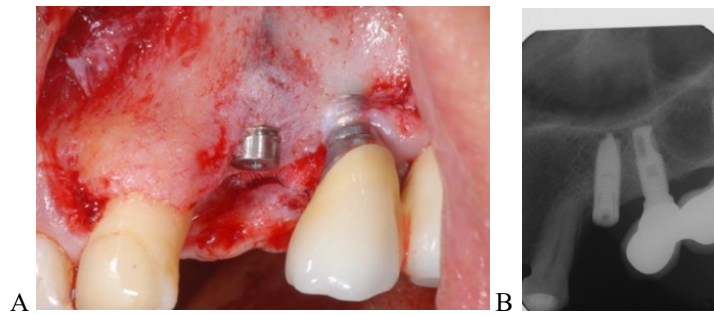


Fig. 3. *A) Intraoperative diagnosis of vestibular bone defect: note the most coronal exposed threads and the titanium metallic color in transparency indicating a very thin vestibular bone ridge. B) Intraoperative periapical radiograph documenting implant placement*

release incision, which is extremely superficial so that a completely tension-free flap is obtained. A small, sterile gauze is placed inside the palatal flap to keep the palatine flap slightly retracted during the surgical steps (Fig. 2).

In the implant site, preparatory burs are used according to the protocol. Then, the implant is inserted following drilling (SK1 Shakleton, Brescia, Italy). When the implant placement is completed, the titanium is observed in transparency revealing extremely thin bone tissue that could compromise not so much osseointegration but the prognosis and long-term success of the procedure (Fig. 3).

At the intraoperative examination, a bone architecture characterised by concavity, moderate extent, and the exposure of a thread in the coronal area is observed. Such a deficit, although minimal, considering the length of the implants, could be a risk factor, not for osseointegration but for the long-term stability of the bone volume present, as well as for preserving the peri-implant soft tissues.

With a dedicated cylindrical bur, similar to the PDS II suture diameter, mounted on a low-speed handpiece, multiple perforations of the cortical bone (decortication) were carried out on the surgical bed to increase the access of blood vessels to the site and, therefore, enhance angiogenesis (Fig. 4).

Four of these perforations were strategically prepared in a roughly square configuration, with the holes opposing each other in the corners of this geometric form (Fig. 4). two segments of polydioxanone suture (PDS II, Ethicon, Johnson & Johnson, Cincinnati – OH, USA) were cut to the desired length (approximately 18 mm) to create a “dome-like” effect.

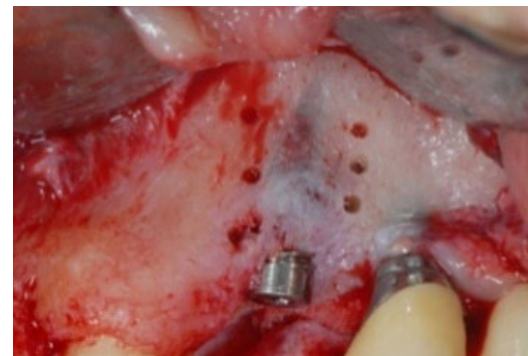


Fig. 4. *Cortical perforations are made in order to involve undifferentiated mesenchymal cells within the underlying bone cavities in the healing process.*

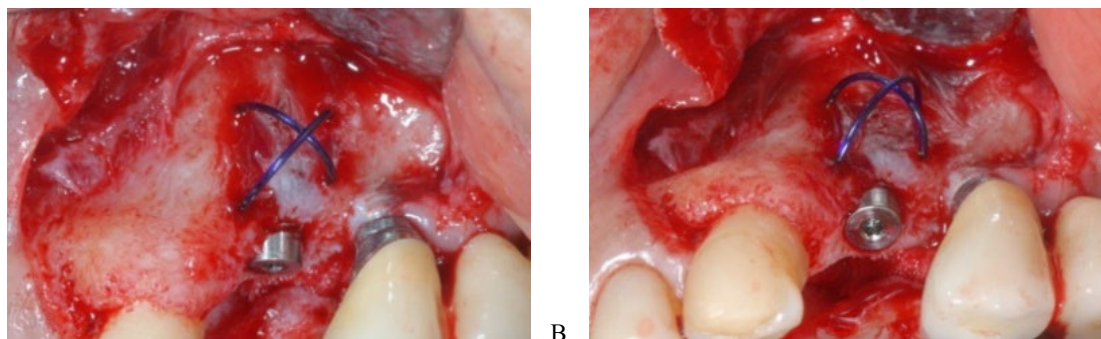


Fig. 5. *A) Placement of PDSII resorbable sutures within 4 previously created holes and crisscrossed. B) Occlusal view of the device creating a domed architecture.*

One extremity of each polydioxanone segment was placed in one of the holes and bent until the other extremity was placed in the opposite hole, forming a dome-shaped structure (Fig. 5).

Autogenous bone chips, locally collected with a bone scraper in combination with a resorbable xenograft UGEN BM REBONE01L (Cancellous Bone) (Vigonza Pd Italy), were placed under the dome, filling the space created by the PDSII suture threads (Fig. 6).

The regenerative material was then covered and protected with a cross-linked resorbable collagen membrane (OsseoGuard Membrane, Zimmer Biomet, Oakland, New Jersey USA) and trimmed and adapted above the domed device to enfold the bone deficit completely (Fig. 7). The membrane is then stabilised with horizontal periosteal mattress stitches on the vestibular side, apical to the membrane, intramural, internal, and in the palatal flap thickness. An additional vertical periosteal mattress suture stabilises the mesial-to-distal membrane exploiting the neighbouring periosteum (Fig. 7).

The previously passivated vestibular flap is sutured coronally to achieve complete coverage of the membrane and the regenerative material. Primary wound closure of the flap was obtained with single interrupted and/or horizontal mattress sutures, using resorbable and PTFE suture threads (Fig. 8). Antibiotics were prescribed: amoxicillin + clavulanic acid, 1 g every 12 hours, two hours before surgery and for the next 4 days, and pain medication as needed. The patient is motivated to appropriate home care.

Patients were instructed to avoid mechanical trauma and tooth brushing for 2 weeks in the surgical area. They used a 0.12% chlorhexidine-soaked gauze three times a day (Digital Brush, Enacare, Micerium, Avegno, Ge, Italy), twice a day for the first two weeks, with a rolling motion in the apico-coronal direction, starting from the alveolar mucosa.

The postoperative progression was free of complications in the first 10 months after surgery. At each follow-up visit, there were no signs of plaque-induced inflammation: the patient reported no discomfort or signs of oedema. The implant remained completely submerged throughout the healing phase (Fig. 9).

At the second surgical stage, a partial-thickness flap is done for prosthetic abutment connection to create a bleeding recipient site for harvesting soft tissue from the palate. A pronounced convexity of the periodontal tissues is appreciated, especially from an occlusal view following flap elevation (Fig. 10).

A small periosteal incision reveals neo-formation tissue that mimics the desired volume previously obtained with resorbable materials (Fig. 11). An epithelial-connective graft is harvested from the palate to create an adequate band of keratinised tissue to improve the long-term prognosis of the regenerative technique. The graft was planned, of adequate length, to extend to the distal implant and protect the most coronal threads. Most clinicians agree that an “adequate” amount of adherent gingiva around an implant-supported prosthetic reconstruction facilitates adequate oral hygiene, ensuring greater predictability for long-term clinical stability (17-18).

The epithelial-connective graft harvested from the palate is sutured with horizontal periosteal stabilising mattress stitches around the tooth, the healing abutment and the prosthetic restoration to ensure its intimate contact with the

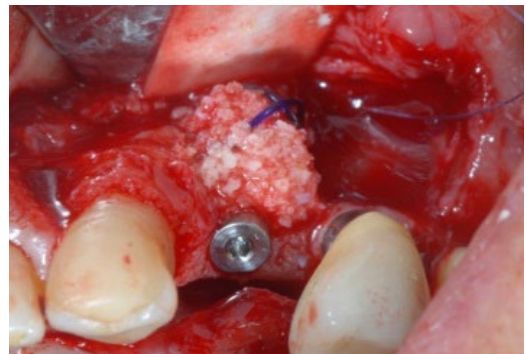

Fig. 6. Placement of the filling material underneath the dome.

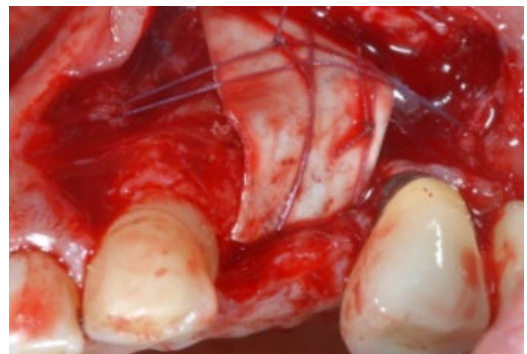

Fig. 7. Suturing the resorbable membrane covering the dome device and regenerative material. Vertical and horizontal periosteal stabilization sutures.

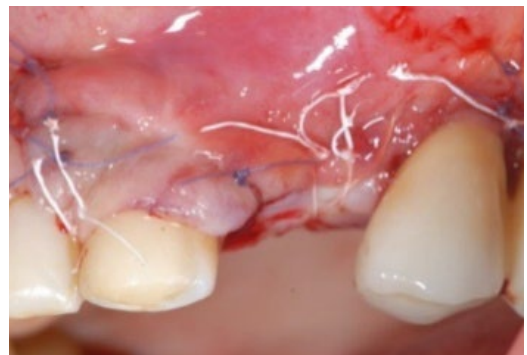

Fig. 8. Suturing flap technique with first intention closure achieved with resorbable threads and PTFE following completion of the first surgical phase.

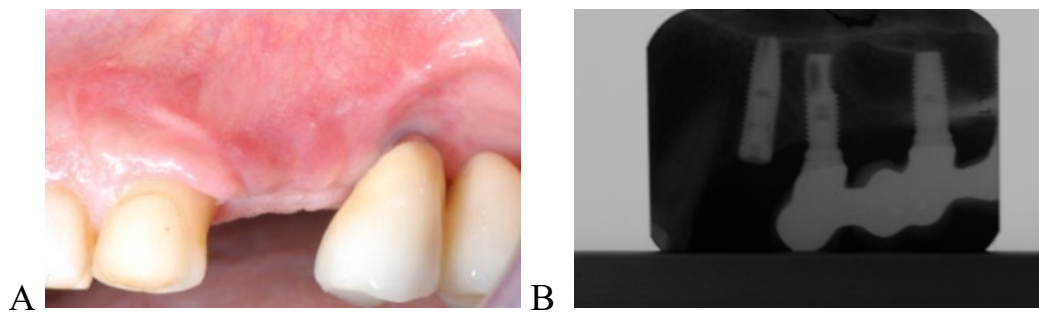


Fig. 9. *A) Clinical aspect of the left maxillary area at the time of implant uncovering 10 months after the first surgical phase. B) Follow-up radiograph at 10-month check-up.*

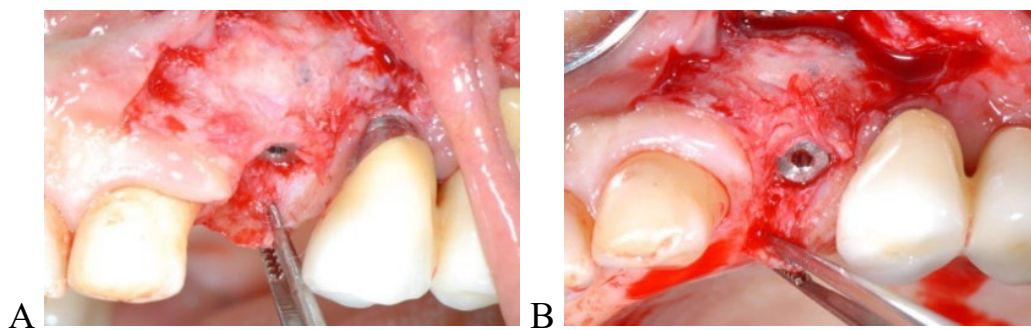


Fig. 10. *A) Implant surgical phase II: complete coverage of the coils and increased bone thickness is evident. B) Occlusal view of the neoformation tissue of which the convexity obtained is clearly visible.*

underlying periosteum. The buccal flap is sutured apically to the graft and anchored with simple periosteal stitches. This therapeutic option allows the clinician to obtain a greater band of keratinised tissue around the implants and deepen the fornix (Fig. 12). The graft was placed apically to the previously exposed implant-prosthetic structure of the second premolar. This clinical situation was stable over time and had never been a matter of complaint and discomfort for the patient.

Sutures are removed on day 7 and day 14. The patient is enrolled in a hygiene maintenance program with periodic recalls every 4 months, and the site is also documented radiographically and clinically every year. Periodontal tissue stability at a 6-year follow-up is observed (Fig. 13).

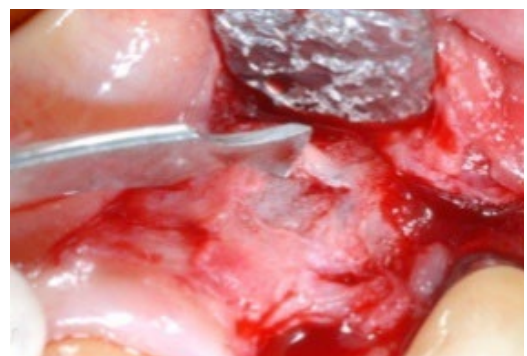


Fig. 11. *Small incision of the periosteum for the purpose of assessing the reduced connective tissue thickness covering the neoformation tissue obtained.*

DISCUSSION

The treatment plan included an implant insertion replacing the left maxillary first premolar, presenting a horizontal bone thickness deficit. For the presence of a residual, extremely thin bone, disclosing “in transparency” all vestibular threads, a bony reconstructive technique with a “2-stage” GBR approach was fully recommended. A regenerative technique is not necessary based on specific assessments. Nonetheless, in cases where the cortical bone is extremely reduced, additionally associated with very low blood nourishment, consequently more unstable and vulnerable conditions are established for both soft and hard tissues, conversely desiring to promote long-term maintenance (13, 19, 20).

As mentioned earlier, the clinician has multiple available regenerative techniques (4-6). However, those risks related to the exposition of metal components, such as titanium meshes or fixation screws, to the oral cavity during the healing phase that are excluded since the polydioxanone dome technique allows a “metal-free” GBR should not be forgotten. Therefore, this method stands out as a possibility for bone reconstruction with simultaneous implant placement, which benefits patients and surgeons, reducing the number of interventions and the overall treatment time.

Considering the above premises, it is the author’s opinion that an increase in bone tissue thickness, quality and quantity of keratinised mucosa around the implant will minimise both suffering and consequent shrinkage during osseointegration prior to and after healing, and not least endorsing better aesthetic outcomes. Clinically, the goal is to provide around the implants an adequate volume of bone support, following the first surgical phase and an adequately thick and fibrotic mucosal seal, in the second phase, with the use of an epithelial-connective graft.

Thus, PDS II resorbable suture filaments, in the present case report, proved to be an effective device to achieve a dome effect, which can promote the biological principles of GBR, creating space and maintaining it for about 6 months. The regenerative material used to protect and stabilise the blood clot will undergo a resorption process over 9 months.

However, the achieved regeneration success was ensured by adhered GBR principles and concepts: coagulum stabilisation, cellular selectivity enhanced by the resorbable membrane and closure by the first intention due to flap passivation. Still, the dome structure was crucial to maintain adequate space over time.

In the present case report, the second surgical phase was planned to respect the bone neo-formation time frame and, once implant osseointegration was achieved, devote a second surgery entirely to soft tissue reconstruction. However, this regenerative approach can be implemented in a single “1-stage” surgical procedure, providing the benefit of avoiding a surgical reoperation, reducing patient discomfort, as well as limiting the time for aesthetic and functional finalisation. The increased buccal bone thickness achieved may play an important role in the bone stability and aesthetics of the soft tissues surrounding the implants, thereby supporting their long-term prognosis (21-23).

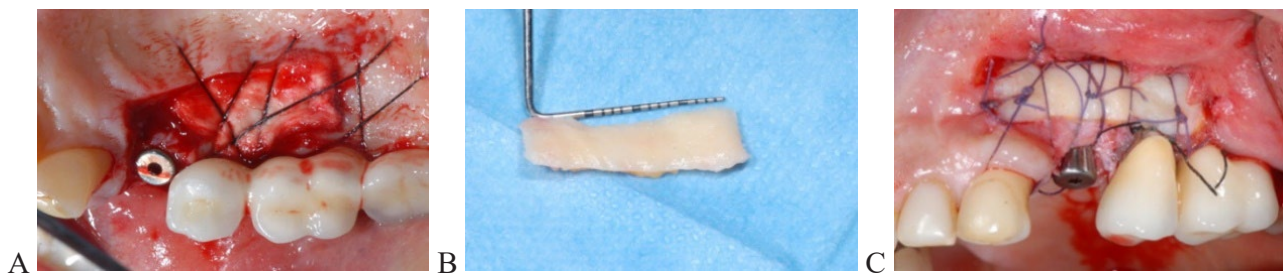


Fig. 12. *A) Area of the epithelial-connective sampling performed in the palate and sutured buccally with crossed, knotted horizontal mattress stitches. A collagen hemostatic material was placed below the silk sutures. B) Extraoral photo of the sampling to document its length. C) Suture of the harvested graft and buccal flap.*

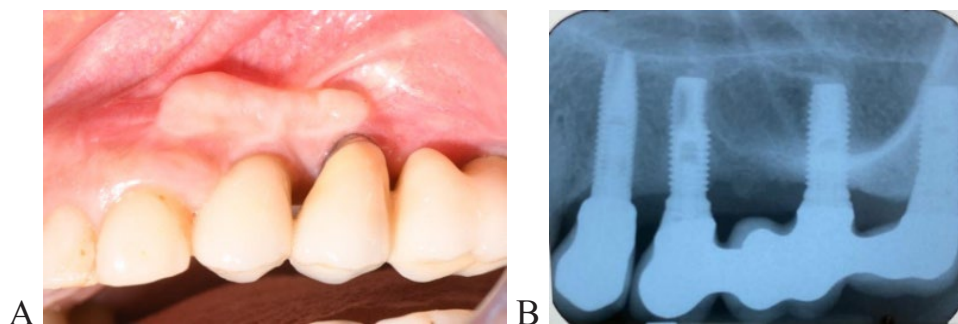


Fig. 13. *A) A 6-year follow-up clinical view. B) A 6-year x-ray follow-up.*

Despite the bony regenerative and reconstructive mucogingival results, it will still be imperative to enrol the patient in a maintenance program with professional hygiene sessions every 3 months to maintain implant health and avoid plaque-induced inflammation.

CONCLUSION

This proof of principle case report demonstrated that the PDS II absorbable suture material, used to create a “dome” effect, in association with regenerative techniques around the implants, could be a valid space maintainer for a sufficient time, to allow adequate bone regeneration, also in association with other resorbable regenerative materials. Moreover, thanks to such a device, all the GBR principles essential for regenerative success have been followed, such as: maintaining space, blood clot stabilisation and flap closure by primary intention.

REFERENCES

1. Albrektsson T, Zarb G, Worthington P, Eriksson AR. The long-term efficacy of currently used dental implants: a review and proposed criteria of success. *The International Journal of Oral & Maxillofacial Implants*. 1986;1(1):11-25.
2. Leonhardt A, Grondahl K, Bergstrom C, Lekholm U. Long-term follow-up of osseointegrated titanium implants using clinical, radiographic and microbiological parameters. *Clinical Oral Implants Research*. 2002;13(2):127-132. doi:10.1034/j.1600-0501.2002.130202.x
3. Schropp L, Wenzel A, Kostopoulos L, Karring T. Bone healing and soft tissue contour changes following single-tooth extraction: a clinical and radiographic 12-month prospective study. *The International Journal of Periodontics & Restorative Dentistry*. 2003;23(4):313-323.
4. Barone A, Covani U. Maxillary Alveolar Ridge Reconstruction With Nonvascularized Autogenous Block Bone: Clinical Results. *Journal of Oral and Maxillofacial Surgery*. 2007;65(10):2039-2046. doi:10.1016/j.joms.2007.05.017
5. Vercellotti T. Piezoelectric surgery in implantology: a case report--a new piezoelectric ridge expansion technique. *The International Journal of Periodontics & Restorative Dentistry*. 2000;20(4):358-365.
6. Chiapasco M, Romeo E, Casentini P, Rimondini L. Alveolar distraction osteogenesis vs. vertical guided bone regeneration for the correction of vertically deficient edentulous ridges: A 1-3-year prospective study on humans. *Clinical Oral Implants Research*. 2004;15(1):82-95. doi:10.1111/j.1600-0501.2004.00999.x
7. Dahlin C, Simion M, Hatano N. Long-Term Follow-Up on Soft and Hard Tissue Levels Following Guided Bone Regeneration Treatment in Combination with a Xenogeneic Filling Material: A 5-Year Prospective Clinical Study. *Clinical Implant Dentistry and Related Research*. 2010;12(4):263-270. doi:10.1111/j.1708-8208.2009.00163.x
8. Kuchler U, Chappuis V, Gruber R, Lang NP, Salvi GE. Immediate implant placement with simultaneous guided bone regeneration in the esthetic zone: 10-year clinical and radiographic outcomes. *Clinical Oral Implants Research*. 2015;27(2):253-257. doi:10.1111/clr.12586
9. Hammerle CHF, Jung RE, Feloutzis A. A systematic review of the survival of implants in bone sites augmented with barrier membranes (guided bone regeneration) in partially edentulous patients. *Journal of Clinical Periodontology*. 2002;29(s3):226-231. doi:10.1034/j.1600-051x.29.s3.14.x
10. Nyman SR, Lang NP. Guided tissue regeneration and dental implants. *Periodontology 2000*. 1994;4(1):109-118. doi:10.1111/j.1600-0757.1994.tb00011.x
11. Rocchietta I, Ferrantino L, Simion M. Vertical ridge augmentation in the esthetic zone. *Periodontology 2000*. 2018;77(1):241-255. doi:10.1111/prd.12218
12. Dahlin C, Andersson L, Linde A. Bone augmentation at fenestrated implants by an osteopromotive membrane technique. A controlled clinical study. *Clinical Oral Implants Research*. 1991;2(4):159-165. doi:10.1034/j.1600-0501.1991.020401.x
13. Dahlin C, Lekholm U, Becker W, et al. treatment of fenestration and dehiscence bone defects around oral implants using the

- guided tissue regeneration technique: a prospective multicenter study. *The International Journal of Oral & Maxillofacial Implants*. 1995;10(3):312-318.
14. Tinti C, Parma-Benfenati S, Polizzi G. Vertical ridge augmentation: what is the limit? *The International Journal of Periodontics & Restorative Dentistry*. 1996;16(3):220-229.
 15. Hempton TJ, Fugazzotto PA. Ridge augmentation utilising guided tissue regeneration, titanium screws, freeze-dried bone, and tricalcium phosphate: Clinical report. *Implant Dentistry*. 1994;3(1):35-37. doi:10.1097/00008505-199404000-00006
 16. Benic GI, Hämmerle CHF. Horizontal bone augmentation by means of guided bone regeneration. *Periodontology 2000*. 2014;66(1):13-40. doi:10.1111/prd.12039
 17. Schrott AR, Jimenez M, Hwang JW, Fiorellini J, Weber HP. Five-year evaluation of the influence of keratinized mucosa on peri-implant soft-tissue health and stability around implants supporting full-arch mandibular fixed prostheses. *Clin Oral Implants Res*. 2009;20(10):1170-1177. doi:10.1111/j.1600-0501.2009.01795.x
 18. Gobbato L, Avila-Ortiz G, Sohrabi K, Wang CW, Karimbux N. The effect of keratinized mucosa width on peri-implant health: a systematic review. *Int J Oral Maxillofac Implants*. 2013;28(6):1536-1545. doi:10.11607/jomi.3244
 19. Simion M, Jovanovic SA, Tinti C, Benfenati SP. Long-term evaluation of osseointegrated implants inserted at the time or after vertical ridge augmentation. A retrospective study on 123 implants with 1-5 year follow-up. *Clin Oral Implants Res*. 2001;12(1):35-45. doi:10.1034/j.1600-0501.2001.012001035.x
 20. Parma-Benfenati S, Roncati M, Galletti P, Tinti C. Resorbable dome device and guided bone regeneration: an alternative bony defect treatment around implants. A case series. *Int J Periodontics Restorative Dent*. 2014;34(6):749-755. doi:10.11607/prd.2128
 21. Cairo F, Pagliaro U, Nieri M. Soft tissue management at implant sites. *J Clin Periodontol*. 2008;35(8 Suppl):163-167. doi:10.1111/j.1600-051X.2008.01266.x
 22. Fu JH, Lee A, Wang HL. Influence of tissue biotype on implant esthetics. *The International Journal of Oral & Maxillofacial Implants*. 2011;26(3):499-508.
 23. Rocuzzo M, Grasso G, Dalmaso P. Keratinized mucosa around implants in partially edentulous posterior mandible: 10-year results of a prospective comparative study. *Clinical Oral Implants Research*. 2015;27(4):491-496. doi:10.1111/clr.12563.