



*Original Article*

# **RADIOGRAPHIC EVALUATION OF BUCCAL BONE REMODELLING FOLLOWING IMMEDIATE IMPLANT PLACEMENT AND GRAFTING OF THE FACIAL GAP USING CALCIUM PHOSPHOSILICATE PUTTY**

A. Kaulgud<sup>1</sup>, N. Devkar<sup>2</sup>, S. Dhande<sup>2</sup>, K. Ambildhok<sup>3</sup>, P. Carosi<sup>4\*</sup> and C. Lorenzi<sup>4</sup>

<sup>1</sup>Private Practitioner, Pune, Maharashtra, India.

<sup>2</sup>Department of Periodontology, Sinhgad Dental College and Hospital, Pune, India

<sup>3</sup>Sinhgad Dental College and Hospital, India

<sup>4</sup>PhD in Materials for Sustainable Developments, University of Rome Tor Vergata, 00133 Rome, Italy

*\*Corresponding author:*

Paolo Carosi

Department of Chemical Sciences and Technology,

University of Rome Tor Vergata,

00133 Rome, Italy

e-mail: paolo.carosi@alumni.uniroma2.eu

## **ABSTRACT**

Loss of teeth often leads to buccal plate bone left unsupported along with lack of blood supply further causing resorption of alveolar bone for which a myriad of procedures is available to refrain post-extraction bone loss including immediate implant. This study is aimed to evaluate radiographic outcomes of the alveolar ridge following immediate implant placement associated with the use of a calcium phosphosilicate (CPS) putty bone graft placed between the implant and the inner surface of the buccal alveolar plate. 15 implants were placed with a lingual/palatal orientation immediately after atraumatic extraction. The gap between the internal surface of the socket and the implant surface gap was filled with a CPS putty bone graft. Finally, a healing abutment was placed. CBCT analysis was carried out after immediate implant placement and 6 months post-operatively to assess the horizontal bone changes at the implant platform (L1), the mid implant (L2), and implant apex (L3) levels. Vertical bone height was measured from the implant platform to the buccal bone crest. CBCT analysis was assessed for buccal bone width at L1, L2, and L3 and was decreased at 6 months, similarly palatal bone width at L1 showed no change whereas L2, and L3 showed a decrease at 6 months along with bucco-palatal bone width significantly decreased at 6 months and lastly a minimal decrease was observed in vertical facial height at 6 months. The results were statistically significant. Minimal horizontal peri-implant

Received: 26 November 2023

Accepted: 02 January 2024

Copyright © by BIOLIFE 2024

This publication and/or article is for individual use only and may not be further reproduced without written permission from the copyright holder. Unauthorized reproduction may result in financial and other penalties. **Disclosure: All authors report no conflicts of interest relevant to this article.**

buccal, palatal, and bucco-palatal bone dimensional changes were noted at 6 months after placement of immediate implant and use of Calcium Phosphosilicate putty bone graft. Moreover, minimal vertical facial bone height loss was observed.

**KEYWORDS:** *immediate implant, peri-implant, bone graft, CPS putty bone graft*

## INTRODUCTION

Tooth loss often results in soft and hard tissue changes within the alveolar ridge leading to a reduction in horizontal and vertical dimensions (1). The buccal bone contour loss expected within 3 months after extraction is around 50% (2).

Different techniques have been proposed to prevent ridge resorption such as alveolar ridge preservation (ARP), guided bone regeneration using bone grafts and collagen membranes as barriers with or without immediate implant placement (IIP) (3-7).

Schulte and Heimke in 1976 proposed IIP. Today well-accepted terminology of immediate implantation includes immediate, early, and late placement of implants at the post-extraction sockets (8). Immediate implant placement means implantation at the same time after extraction into the extraction socket. The demand for it has increased especially in anterior sites due to benefits like the decline in the number of surgical interventions, the possibility of immediate provisional restoration, and improved short-term aesthetic outcomes (8, 9). Despite its advantages, it remains a challenge to place an implant matching the extracted tooth dimensions. The gap between the implant and bone is required to be filled in three dimensions with a biocompatible material for enhanced osseointegration (10, 11).

Several graft materials are used for this purpose and these include the use demineralized freeze-dried bone allograft (DFDBA), freeze-dried bone allograft (FDBA), autograft, hard tissue replacement polymer, connective tissue barriers, expanded poly tetra fluoro ethylene (ePTFE) membranes, bio-absorbable membranes, hydroxyapatite (HA), xenografts, use of growth and differentiation factors, particulate and block grafting materials and guided bone regeneration (GBR) (12, 13).

Recently a new generation of putty graft materials has been utilized in bone regeneration procedures with promising results. Putty bone grafts enjoy significantly superior handling characteristics in comparison to particulate grafts. These include ease of placement, enhanced particle containment, and a viscous consistency that has allowed for unique delivery systems to be developed. Calcium Phosphosilicate (CPS) putty bone graft is a pre-mixed composite of bioactive calcium-phospho-silicate particulate combined with polyethylene glycol and glycerine binder. Even though CPS putty is used extensively in regenerative procedures, there is not enough scientific literature about its use in immediate implants (14, 15).

Therefore this study is aimed to evaluate radiographic changes of the alveolar ridge following flapless immediate implant placement associated with the use of a CPS putty bone graft placed between the implant and the inner surface of the buccal alveolar plate.

## MATERIALS AND METHODS

This study was a prospective clinical and radiographic investigation. Clearance from the institutional ethical committee of Sinhgad Dental College and Hospital, Pune was obtained (SDCH/IEC/OUT/2014-15/83, Ref No. SDCH/IEC/IN/2014-15/83).

### *Sample size determination*

Sample size determination is done based on mean and standard deviation values using the following formula:

Sample size formula used:

$$N = (\sigma_1^2 + \sigma_2^2 / \kappa) (Z_1 - \alpha / 2 + Z_1 - \beta)^2$$

$$\Delta^2 = \frac{2 \times 1.96 \times 1.96 \times 0.65 \times 0.65}{0.5 \times 0.5} = 12.98$$

The notations for the formulae are:

N = sample size

$\sigma_1$  = standard deviation of Group 1

$\sigma_2$  = standard deviation of Group 2

$\Delta$  = difference in group means

$\kappa$  = ratio = 1

$Z_{1-\alpha/2}$  = two-sided Z value (eg.  $Z=1.96$  for 95% confidence interval).

$Z_{1-\beta}$  = power

Hence the minimum sample size is 13. Considering a 10% attrition rate we considered the total sample size as 15 in the present study.

#### *Inclusion criteria*

Systemically healthy patients between the age group 20 – 45 years.

Patients in need of extraction and implant placement of any incisor, canine, or premolar tooth.

Indications for extraction include trauma, endodontic treatment failure, or non-restorable carious teeth.

Teeth with healthy periodontium.

Alveolar sockets with 4 wall architecture and intact labial plate.

Patients willing to participate and sign an informed consent.

Compliant patients.

#### *Exclusion criteria*

Patients who are systemically compromised.

Current smokers and patients have a history of smoking.

The patient has a history of bone disorders.

Teeth having acute periapical or periodontal pathology.

Pregnant and lactating females.

Parafunctional habits.

Compromised soft tissue conditions at the surgical site.

Extraction sockets with one or more bony walls damaged.

Informed consent was obtained from all selected patients, and they were informed about the study verbally as well as a written information sheet before extraction and implant placement. A pre-operative CBCT scan (Promax 3D, Planmeca, Helsinki, Finland) was taken to study the bony architecture and for the selection of the implant size.

The implants used for this study were tapered implants (Touareg-S, Adin Dental Implant Systems, Israel) with a spiral tap having SLA alumina oxide blasted/acid etched surface treatment.

#### *Pre-surgical procedure*

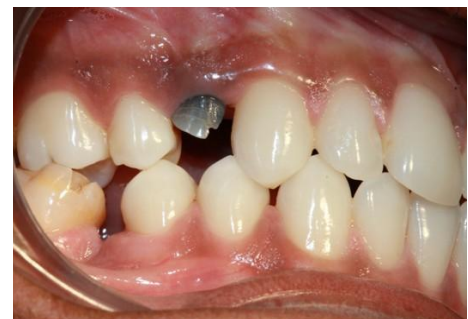All procedures from pre-operative assessment to post-operative follow-up were carried out by a single operator. All the patients recruited for the study underwent oral prophylaxis.

Pre-operatively, the patients received an antibiotic regimen (1g Amoxicillin 1 hour before surgery, followed by 500 mg three times a day for 5 days).

#### *Surgical procedure*

Atraumatic extraction of the indicated teeth was carried out by the operator without elevation of the periodontal flap under local anesthesia (2% Lidocaine with 1:100000 adrenaline) using periostomes, elevators and extraction forceps as required (Fig. 1, Fig.2).

Dimensions of extracted root pieces were measured before implant placement. The extraction socket was assessed to confirm the integrity of the alveolar socket (Fig 3).



**Fig. 1.** Pre-operative photograph



**Fig. 2.** Novabone Dental Putty Cartridge delivery system

The osteotomy preparation was carried out using sequential drilling without raising a flap towards the lingual/palatal wall of the socket. The required size of the dental implant was placed to a level 1-2 mm apical to the buccal alveolar crest and with a lingual/palatal orientation. This resulted in a gap between the internal surface of the socket and the implant surface. The gap was further filled with a synthetic particulate graft material using a cartridge delivery system (Novabone bioactive synthetic bone graft dental putty, Osteogenic Biomedicals, Lubbock, USA) (Fig. 4).

Finally, a healing abutment that occupied most of the socket and reflecting coronal to the gingival margin was placed.

Subsequently, a cone beam computed tomography (CBCT) scan was carried out post-operatively (Day 0 / Baseline) using Carestream CBCT Machine 9000 3D, USA, with exposure time 13 – 18 sec, with 60 – 90 Kvp, 8 mA-s and repeated after 6 months.

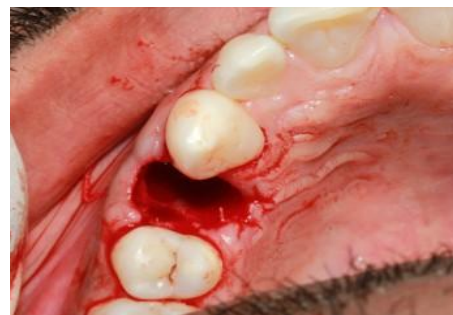Patients were advised to follow the standard post-operative instructions and were advised to rinse with 0.12% chlorhexidine twice a day for 14 days postoperatively.

Following CBCT measurements were done at baseline (day 0) and at 6 months (Fig. 5, Fig. 6, Fig. 7).

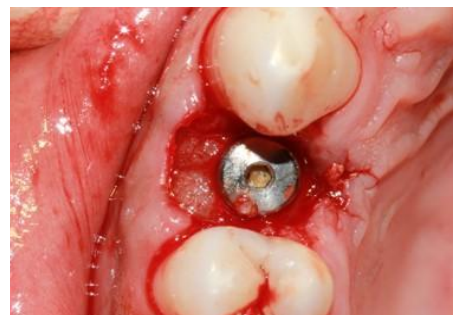Horizontal measurements: Buccal wall thickness, palatal wall thickness, and total bucco-palatal width from the external surface of the buccal and palatal/lingual alveolar plates to the implant surfaces were carried at the platform (L1), middle (L2), and apical (L3) levels of the implant.

Vertical measurement: Vertical facial bone level was measured on the facial surface of the implant as the perpendicular distance from the implant platform to the most coronal point of the facial bone.


The healing abutment remained in place during the entire 6-month observation period. All the participants were instructed to maintain oral hygiene and were seen at regular intervals of 1 week, 15 days, 1 month, 3 months, and 6 months. During the 6 months, all participants were given fiber reinforced acrylic provisional restorations, which did




**Fig. 3.** Integrity of the alveolus checked post-extraction



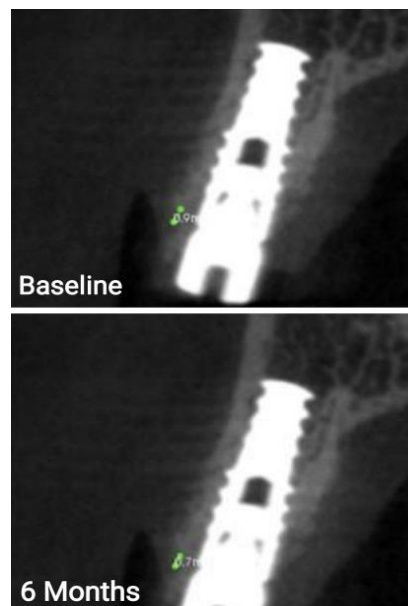
**Fig. 4.** Novabone Dental Putty synthetic bone graft material placed between the implant surface and buccal bone



**Fig. 5.** Bucco-palatal CBCT measurements recorded at Baseline (Day 0) and 6 Months



**Fig. 6.** Buccal and Palatal CBCT measurements recorded at Baseline (Day 0) and 6 Months



**Fig. 7.** Vertical CBCT measurements recorded at Baseline (Day 0) and 6 Months

not encroach on the gingival former. After 6 months post-extraction, all participants were recalled for the radiographic measurements. The implants were restored 6 months after the placement.

### Statistical analysis

Data collected was compiled into an MS Office Excel worksheet and was subjected to statistical analysis using Social Sciences (SPSS) version 21.0. Descriptive statistics like frequency (n) and percentage (%) of categorical data, mean and Standard deviation of numerical data in each group were depicted.

The normality of numerical data was checked using the Shapiro – Wilk test or Kolmogorov-Smirnov test. Since the data was normally distributed, parametric statistical tests were used in the study. Keeping alpha error at 5% and Beta error at 20%, power at 80%,  $p < 0.05$  will be considered statistically significant.

The data was collected by measuring buccal wall thickness, palatal wall thickness, total bucco- palatal width, and vertical facial bone alveolar ridge height at baseline (day 0) and after 6 months in mm. The comparison between time intervals i.e., 0 and 6 months was calculated using Paired 't'-test. A frequency distribution table was used for teeth distribution and gender distribution. Descriptive analysis was used to evaluate the mean and standard deviation for bone height and width.

## RESULTS

A total of 9 patients (5 males and 4 females; average age – 31.2 years, with a total of 15 extraction sites in the upper jaw and lower jaw (13 sites and 2 sites respectively; Central incisors – 4, Lateral incisors – 3, Canines – 1, Pre molars – 7) were treated with palatally placed immediate implants along with the CPS putty bone graft placed in the gap between implant and buccal/ labial plate.

No postoperative complications were recorded at any included site. All patients completed the study. The CBCT measurements (Baseline and 6 months) were carried out and are summarized in Tables No 1,2,3,4 and Graph No 1,2,3,4.

The CBCT findings for buccal bone width (Table I) showed that there was a slight decrease in the buccal bone width at L1, L2, and L3 levels after immediate implant placement.

The CBCT findings for palatal bone width (Table II) showed that there was no change at L1 while slight decrease in the palatal bone width at L2 and L3 levels after immediate implant placement.

The CBCT findings for bucco-palatal bone width (Table III) showed that there was a slight decrease in the bone width at L1, L2, and L3 levels after immediate implant placement.

The CBCT findings for vertical facial bone height (Table IV) showed that there was a slight decrease in the vertical facial bone height after immediate implant placement.

The correlation coefficient showed a high correlation and statistically significant difference between baseline and 6 months for buccal, palatal, and bucco-palatal width at L1, L2, and L3 levels (Graph 1,2,3,4).

Vertical facial bone height difference showed less correlation and was not statistically significant. Comparison of mean differences in measurements of buccal bone width for baseline and 6 months showed statistically significant change at L1, L2, and L3 levels. Comparison of mean differences in measurements of palatal bone width for baseline

**Table I.** Comparison of mean differences of buccal bone width at baseline and 6 months

<u>Level Measurements</u>		<u>Mean difference</u>	<u>t value</u>	<u>P value</u>
<u>L1</u> (Coronal of implant)	<u>Baseline</u>	<u>0.28</u>	<u>6.54</u>	<u>P &lt; 0.05</u>
	<u>6 months</u>			
<u>L2 Level</u> (Middle of implant)	<u>Baseline</u>	<u>0.20</u>	<u>5.12</u>	<u>P &lt; 0.05</u>
	<u>6 months</u>			
<u>L3 Level</u> (Apical of implant)	<u>Baseline</u>	<u>0.18</u>	<u>5.33</u>	<u>P &lt; 0.05</u>
	<u>6 months</u>			



**Table II.** Comparison of mean differences of palatal bone width at baseline and 6 months

Measurements		Mean difference	t value	P value
L1 Level (Coronal of implant)	Baseline	0.00	0.00	1.00
	6 months			
L2 Level (Middle of implant)	Baseline	0.20	3.94	0.001
	6 months			
L3 Level (Apical of implant)	Baseline	0.22	3.97	0.001
	6 months			

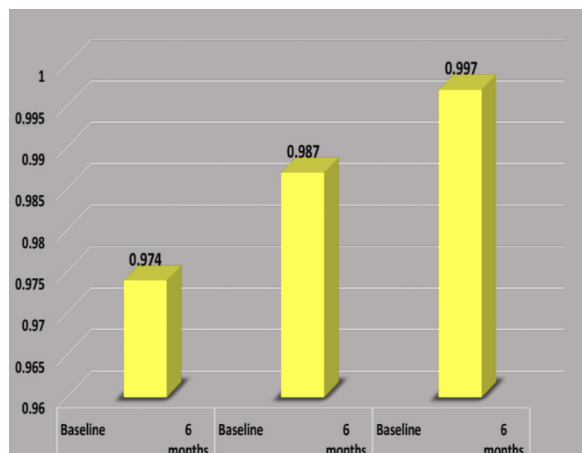
**Table III:** Comparison of mean differences of bucco - palatal bone width at baseline

Measurements		Mean difference	t value	P value
L1 Level (Coronal of implant)	Baseline	0.67	4.25	0.001
	6 months			
L2 Level (Middle of implant)	Baseline	0.68	4.71	P<0.05
	6 months			
L3 Level (Apical of implant)	Baseline	0.54	4.93	P<0.05
	6 months			

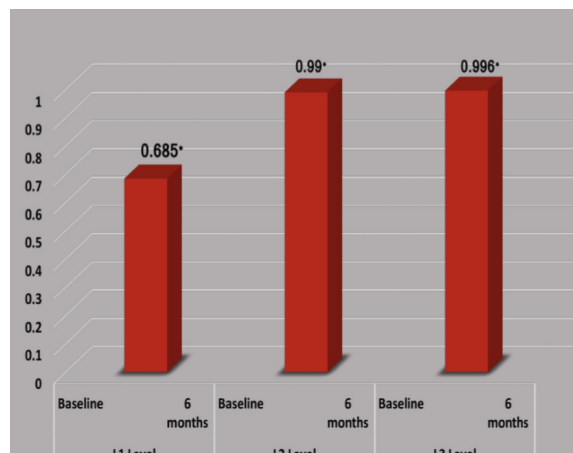
and 6 months showed no significant difference at L1 while statistically significant change at L2 and L3 levels. Comparison of mean differences in measurements of Bucco-palatal bone width for baseline and 6 months showed statistically significant change at L1, L2, and L3 levels. Comparison of mean differences in measurements of vertical facial bone height for baseline and 6 months showed statistically significant change.

**Table IV:** Comparison of mean differences of vertical facial bone height at baseline

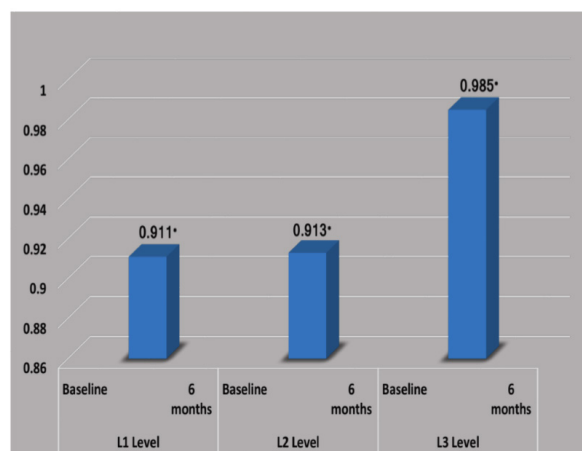
Measurements		Mean difference	t value	P value
L1 Level (Coronal of implant)	Baseline	0.67	4.25	0.001
	6 months			
L2 Level (Middle of implant)	Baseline	0.68	4.71	P<0.05
	6 months			
L3 Level (Apical of implant)	Baseline	0.54	4.93	P<0.05
	6 months			



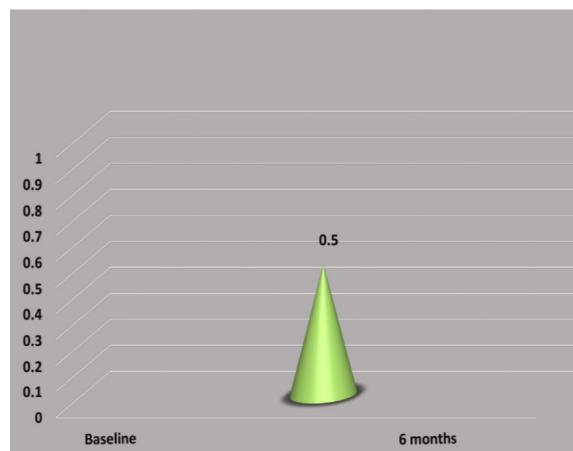
**Graph 1.** Correlation of buccal bone width at baseline and 6 months



**Graph 2.** Correlation of palatal bone width at baseline and 6 months



**Graph 3.** Correlation of bucco-palatal width at baseline and 6 months



**Graph 4.** Correlation of vertical bone height at baseline and at 6 months

## DISCUSSION

The present radiographic study was carried out to assess the horizontal alveolar ridge changes on facial and palatal cortical plates, total bucco-lingual dimensional changes, and the vertical buccal alveolar ridge changes after placement of immediate implant associated with synthetic bone graft. The data clearly demonstrated preservation of the buccal alveolar bone thickness up to a 6-month period. Several studies have demonstrated similar results.

Roe et al. (16) evaluated the changes in horizontal facial bone thickness (HFBT) at 7 different levels compared to 3 in our study. The vertical facial bone level (VFBL) measurement was similar to our study. The mean HFBT changes ranged from  $-1.23$  to  $-0.08$  mm while the mean VFBL change was  $-0.82$  mm. In comparison, the present study showed mean difference of facial bone height as 1.28. The mean difference in facial bone width changes was more at the implant platform level (0.28) than at L2 mid-implant level (0.20) and L3 apical level of the implant (0.18).

The horizontal facial bone width measurements taken in our study were similar to the study by Lee et al. (17). However, we also added palatal bone width, bucco-palatal width and the vertical measurement. The graft used in Lee et al. was bovine derived particulate graft. The study interval of baseline and 6 months CBCT was similar to our study. However, we did not use immediate implant supported provisional as in Lee et al. Results of both studies are similar in showing non significant resorption of buccal bone.

In a study by Botticelli et al. (18) no membranes or filler material was used. The flaps were subsequently replaced and secured with sutures in such a way that the healing cap of the implant was exposed to the oral environment. No radiographic measurements were done and the clinical measurements were done at baseline and 4 months after re-entry surgery. They noted that the horizontal resorption of the buccal bone dimension amounted to about 56%. The corresponding resorption of the lingual/palatal bone was 30%. The vertical bone crest resorption amounted to  $0.3 \pm 0.6$  mm (buccal). In our study also the immediate placement of dental implant with bone graft materials did not prevent the peri-implant bone remodelling.

Lee et al. checked alteration of bone dimension following immediate implant placement in a systematic review and meta-analysis. A total of 6 studies were included. The weighted mean buccal horizontal bone dimensional reduction was 1.07 mm and buccal vertical bone dimensional reduction was 0.78 mm. The weighted mean palatal bone dimensional reduction was 0.62 mm horizontally and 0.50 mm vertically.

Another study carried out by Assaf et al. (2) assessed computed tomographic alterations of the buccolingual width of the alveolar ridge after immediate implant placement associated with the use of a synthetic biphasic calcium sulphate in 20 extraction sites in 20 patients. They used a healing cap like the current study. Buccolingual measurement was done at 1mm and 3mm apical to the bone crest. In accordance with our study, the authors concluded that calcium sulphate was capable of preventing the loss of buccolingual dimensions (2).

Tarnow et al. (7) showed that bone grafting at the time of implant placement into the gap in combination with a contoured healing abutment or provisional restoration resulted in the smallest amount of ridge contour change.

These results may be of clinical significance because the maintenance of the buccal wall and buccolingual dimensions of the alveolar ridge after dental implant placements has a positive relationship with the maintenance of the gingival margin, significantly reducing the risk of gingival recession.

Few recent studies have thrown light on multiple aspects of immediate implant placement. Ahmed Ibrahim Aboul Fetouh et al. (20) examined vertical and horizontal changes 1 year following flapless immediate implant with and without xenograft at sites with thin labial plate. This investigation suggested that immediate implants with or without grafting the labial gap preserved alveolar bone dimension and that bone formation labial to the implant was related to initial labio-palatal socket dimension.

Perez A et al. (21) showed that the customized healing abutment group showed the most favorable outcomes (in terms of papilla index and marginal bone level) in case of immediate implant that received a periimplant bone grafting procedure.

Mao et al. (22) included 4 randomized controlled trials and 12 nonrandomized controlled trials for systematic review and meta-analysis. This study demonstrated that immediate implant placement in the esthetic zone does not prevent buccal bone from resorption.



Levine et al. (23) showed that sites with wider gap (>2mm) exhibited a significantly thicker newly formed buccal bone wall and, a higher percentage of its buccal aspect covered by bone than sites in the wide gap group (<2mm).

The possible reasons for preservation of the buccal and palatal bone in our study are flapless technique and use of a CPS putty graft. Limitations of the present study were limited sample size, randomization, and split-mouth design was not considered, no histomorphometry analysis was performed to check the bone formed, and no soft tissue assessment and abutment-supported provisionalization of the implant was not considered.

## CONCLUSION

Overall minimal horizontal peri-implant buccal, palatal, bucco-palatal, and vertical bone dimensional changes were observed at 6 months upon placement of immediate implant placement along with simultaneous use of CPS putty bone graft.

## REFERENCES

1. Tan WL, Wong TL, Wong MC, Lang NP. A systematic review of post-extraction alveolar hard and soft tissue dimensional changes in humans. *Clin Oral Implants Res.* 2012;23 Suppl 5(1-21). doi:<https://doi.org/10.1111/j.1600-0501.2011.02375.x>
2. Assaf JH, Zanatta FB, de Brito RB, Jr., Franca FM. Computed tomographic evaluation of alterations of the buccolingual width of the alveolar ridge after immediate implant placement associated with the use of a synthetic bone substitute. *Int J Oral Maxillofac Implants.* 2013;28(3):757-763. doi:<https://doi.org/10.11607/jomi.2719>
3. Donos N, Mardas N, Chadha V. Clinical outcomes of implants following lateral bone augmentation: systematic assessment of available options (barrier membranes, bone grafts, split osteotomy). *J Clin Periodontol.* 2008;35(8 Suppl):173-202. doi:<https://doi.org/10.1111/j.1600-051X.2008.01269.x>
4. Pozzi A, Arcuri L, Carosi P, Nardi A, Kan J. Clinical and radiological outcomes of novel digital workflow and dynamic navigation for single-implant immediate loading in aesthetic zone: 1-year prospective case series. *Clin Oral Implants Res.* 2021;32(12):1397-1410. doi:<https://doi.org/10.1111/clr.13839>
5. Fukuba S, Okada M, Nohara K, Iwata T. Alloplastic Bone Substitutes for Periodontal and Bone Regeneration in Dentistry: Current Status and Prospects. *Materials (Basel).* 2021;14(5):doi:<https://doi.org/10.3390/ma14051096>
6. Carosi P, Lorenzi C, Di Gianfilippo R, et al. Immediate vs. Delayed Placement of Immediately Provisionalized Self-Tapping Implants: A Non-Randomized Controlled Clinical Trial with 1 Year of Follow-Up. *J Clin Med.* 2023;12(2):doi:<https://doi.org/10.3390/jcm12020489>
7. Tarnow DP, Chu SJ, Salama MA, et al. Flapless postextraction socket implant placement in the esthetic zone: part 1. The effect of bone grafting and/or provisional restoration on facial-palatal ridge dimensional change—a retrospective cohort study. *Int J Periodontics Restorative Dent.* 2014;34(3):323-331. doi:<https://doi.org/10.11607/prd.1821>
8. Papi P, Di Murro B, Tromba M, Passarelli PC, D'Addona A, Pompa G. The Use of a Non-Absorbable Membrane as an Occlusive Barrier for Alveolar Ridge Preservation: A One Year Follow-Up Prospective Cohort Study. *Antibiotics (Basel).* 2020;9(3):doi:<https://doi.org/10.3390/antibiotics9030110>
9. Lazzara RJ. Immediate implant placement into extraction sites: surgical and restorative advantages. *Int J Periodontics Restorative Dent.* 1989;9(5):332-343.
10. Werbit MJ, Goldberg PV. The immediate implant: bone preservation and bone regeneration. *Int J Periodontics Restorative Dent.* 1992;12(3):206-217.
11. Tomar N, Dahiya S, Sharma PK, et al. A Comparative Clinical Evaluation of Effectiveness of Platelet-Rich Plasma, Synthetic Allograft, and Bioresorbable Xenograft During Immediate Implant Placement. *Cureus.* 2022;14(12):e32121. doi:<https://doi.org/10.7759/cureus.32121>
12. Mahesh L, Salama MA, Kurtzman GM, Joachim FP. Socket grafting with calcium phosphosilicate alloplast putty: a histomorphometric evaluation. *Compend Contin Educ Dent.* 2012;33(8):e109-115.

13. Vignoletti F, Sanz M. Immediate implants at fresh extraction sockets: from myth to reality. *Periodontol 2000*. 2014;66(1):132-152. doi:<https://doi.org/10.1111/prd.12044>
14. Yuan X, Pei X, Zhao Y, et al. Biomechanics of Immediate Postextraction Implant Osseointegration. *J Dent Res*. 2018;97(9):987-994. doi:<https://doi.org/10.1177/0022034518765757>
15. Gehrke SA, da Silva Neto UT, Rossetti PH, Watinaga SE, Giro G, Shibli JA. Stability of implants placed in fresh sockets versus healed alveolar sites: Early findings. *Clin Oral Implants Res*. 2016;27(5):577-582. doi:<https://doi.org/10.1111/clr.12624>
16. Roe P, Kan JY, Rungcharassaeng K, Caruso JM, Zimmerman G, Mesquida J. Horizontal and vertical dimensional changes of peri-implant facial bone following immediate placement and provisionalization of maxillary anterior single implants: a 1-year cone beam computed tomography study. *Int J Oral Maxillofac Implants*. 2012;27(2):393-400.
17. Lee EA, Gonzalez-Martin O, Fiorellini J. Lingualized flapless implant placement into fresh extraction sockets preserves buccal alveolar bone: a cone beam computed tomography study. *Int J Periodontics Restorative Dent*. 2014;34(1):61-68. doi:<https://doi.org/10.11607/prd.1807>
18. Botticelli D, Berglundh T, Lindhe J. Hard-tissue alterations following immediate implant placement in extraction sites. *J Clin Periodontol*. 2004;31(10):820-828. doi:<https://doi.org/10.1111/j.1600-051X.2004.00565.x>
19. Lee CT, Chiu TS, Chuang SK, Tarnow D, Stoupe J. Alterations of the bone dimension following immediate implant placement into extraction socket: systematic review and meta-analysis. *J Clin Periodontol*. 2014;41(9):914-926. doi:<https://doi.org/10.1111/jcpe.12276>
20. Fettouh AIA, Ghallab NA, Ghaffar KA, et al. Bone dimensional changes after flapless immediate implant placement with and without bone grafting: Randomized clinical trial. *Clin Implant Dent Relat Res*. 2023;25(2):271-283. doi:<https://doi.org/10.1111/cid.13178>
21. Perez A, Caiazzo A, Valente NA, Toti P, Alfonsi F, Barone A. Standard vs customized healing abutments with simultaneous bone grafting for tissue changes around immediate implants. 1-year outcomes from a randomized clinical trial. *Clin Implant Dent Relat Res*. 2020;22(1):42-53. doi:<https://doi.org/10.1111/cid.12871>
22. Mao Z, Lee CT, He SM, Zhang S, Bao J, Xie ZG. Buccal bone dimensional changes at immediate implant sites in the maxillary esthetic zone within a 4-12-month follow-up period: A systematic review and meta-analysis. *Clin Implant Dent Relat Res*. 2021;23(6):883-903. doi:<https://doi.org/10.1111/cid.13051>
23. Levine RA, Dias DR, Wang P, Araujo MG. Effect of the buccal gap width following immediate implant placement on the buccal bone wall: A retrospective cone-beam computed tomography analysis. *Clin Implant Dent Relat Res*. 2022;24(4):403-413. doi:<https://doi.org/10.1111/cid.13095>